

The CENTRAL AFRICAN JOURNAL OF MEDICINE

Dr. DAVID LIVINGSTONE

Vol. 3 No. 10.

OCTOBER, 1957.

CONTENTS

ORIGINAL ARTICLES

Surgical Treatment of Portal Hypertension Neuropathy in Kwashiorkor	<i>I. Aird</i>	393
Leprosy in Northern Rhodesia, Part 2	<i>E. Kahn</i>	398
Value of Clinical Research	<i>J. T. Worsfold</i>	401
A Doctor's Life in Africa	<i>Sir Charles Symonds</i>	407
The British National Health Service, Part 2	<i>E. A. Beet</i>	410
A Case of Ornithosis (Psittacosis)	<i>H. Trusson</i>	414
	<i>R. Mossop</i>	418

EDITORIALS

Salt Loss in Chronic Renal Disease	419
A Recent Advance in Endocrinology	419
Placebos	420
Medical Association of Southern Rhodesia	420
Annual Medical Dinner B.M.A. (Mashonaland Branch)	422
Dental Congress in Salisbury	423
Salisbury Cardiac Society	425
"84 Baines"	426
African Clinic, Ndola	427
Correspondence	428
Between Ourselves	428
In Rhodesia Then	429
Book Review	430
The Journal Library	430
Night Duty: African Hospital	431
Medical Council Proceedings	432
Latest Pharmaceutical Preparations	434

PUBLISHED MONTHLY, ANNUAL SUBSCRIPTION £2 2s. 0d.

Registered at the General Post Office as a Newspaper.

A Neuropathy in Children Recovering from Malnutrition (Kwashiorkor)

BY

E. KAHN, M.D., M.R.C.P. (Ed.), D.C.H.
Baragwanath Hospital, Johannesburg.

In two previous publications attention was drawn to an uncommon neurological syndrome observed in 16 children who were recovering from malnutrition (Kahn, 1954; Kahn and Falcke, 1956).

The clinical features of the syndrome can be summarised as follows: Coarse tremors, resembling those of parkinsonism, commence some days or weeks after the faulty diet of a malnourished child has been changed to one consisting mainly or entirely of milk. These tremors affect the extremities, the head, the tongue and sometimes even the abdominal muscles. In some cases the tremors are seen only on one side of the body, while in other instances they may affect the arms only. So far, no case has been observed where tremors have been noted in the legs, but not in the arms. The tremors cease during voluntary movements and during deep sleep. They are often present during light sleep.

Other features of the syndrome are less constant than the tremors. Cog-wheel or lead-pipe rigidity of the limbs is not uncommon. Very often the arms are held in a characteristic position: they are abducted at the shoulders, flexed at the elbows and pronated at the wrist. The fingers are flexed at the metacarpo-phalangeal joints and the thumbs are flexed into the palms.

Muscular weakness is marked in a number of cases and the child may not be able to walk or sit, whereas it was able to do so when admitted to hospital with severe malnutrition. The tendon reflexes are usually exaggerated, there may be some mental irritability or even hallucinations, and there may be myoclonic jerks involving the extremities for a few days while the syndrome is at its worst.

Recovery takes a few days or weeks, or in rare cases several months. The myoclonic jerks usually disappear within the first week. Then follows the mental irritability and next the tremors. The postural abnormalities described above usually continue for several weeks or months after the tremors have ceased.

It is likely that this syndrome occurs in all parts of the world where malnutrition is common, and since it may easily be mistaken for encephalitis, a further three cases of this rather

uncommon syndrome (it occurs in only about one of 300 cases of infantile malnutrition) are described in this paper.

CASE REPORTS

Case 1.—S.M., a seven-months-old African infant, was admitted to Baragwanath Hospital because his arms had been "jerking" for three days.

The child had been receiving treatment at the paediatric out-patients' department for 10 days before admission for an attack of diarrhoea of two weeks' standing. When first seen at the out-patients' department the child was slightly dehydrated and there were signs of malnutrition, but there were no abnormal neurological signs. Treatment for the diarrhoea consisted of a skimmed milk formula, and this was changed two days later to a half-cream milk formula. He also received a sulphonamide mixture and a preparation containing vitamins A and D.

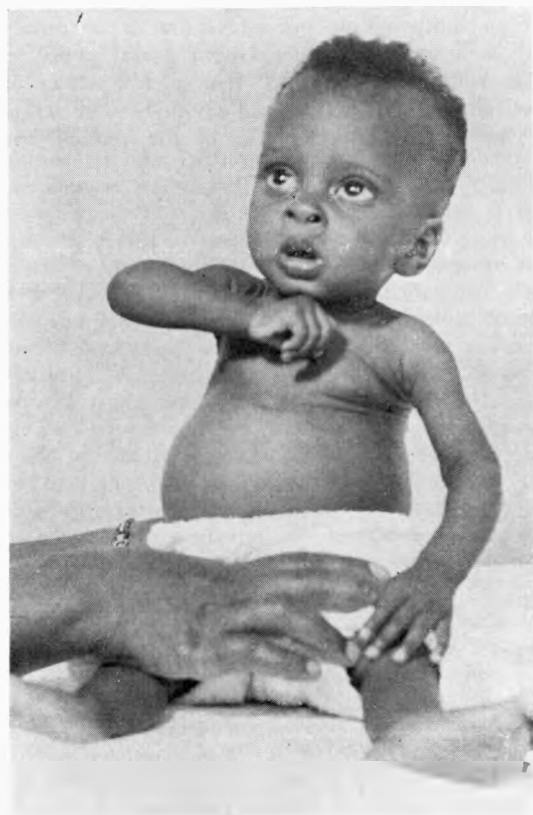


Fig. 1.—Case 1, showing abnormal posture of right arm and open mouth. The child was unable to sit up without support.

The diarrhoea subsided within three days, but 10 days after the diet had been changed to one containing milk the child's arms began to shake, and three days later the parents decided to take the child back to hospital, where it was admitted to the ward.

In the dietetic history of the child it was noted that breast-feeding ceased about six weeks after birth because the mother developed sore nipples. The child was then given sweetened condensed milk, of which one teaspoonful was mixed with one cup of water. Shortly afterwards the diet was changed to a mixture of two dessertspoons of an infant cereal preparation, consisting mainly of baked flour, and six ounces of water. This was given three times a day until after the onset of the above-mentioned attack of diarrhoea.

On admission to hospital the child was found to be markedly underweight at 9 lb. 12 oz. There was depigmentation of the face and the chest and there was marked wasting of the skeletal musculature. The scalp hair was atrophic. However, there was no nutritional dermatosis and there was no evidence of oedema. The liver was not enlarged and there was no diarrhoea.

Examination of the nervous system revealed the following findings: Tremors at a rate of about three oscillations per second were present in the right arm. In addition, a myoclonic reaction was noted every two seconds in this limb, which was affected by a marked cog-wheel rigidity. This extremity was held in a characteristic posture: it was abducted at the shoulder, flexed at the elbow and the hand was held in pronation. The thumb was flexed into the palm (Fig. 1).

The left arm was not affected by tremors, but about every second it was flexed by myoclonic jerks at the elbow. The tongue and the left foot were trembling slightly. The tendon reflexes were markedly exaggerated. The mouth was hanging open constantly, but there was no excessive salivation. The child was unable to sit up unsupported, but there was no clouding of consciousness.

A lumbar puncture performed on admission revealed no abnormalities. Stool culture yielded no pathogens, and the peripheral blood and the bone-marrow were within normal limits.

The neurological findings remained unchanged for two days, but on the third day the myoclonic jerks ceased and the tongue and the left foot stopped trembling. Twelve days after arrival in hospital the child was no longer irritable and he was able to sit up without support. Three weeks after admission all tremors had ceased, but the posture of the right arm was still abnormal. A few weeks later all abnormal neurological signs had disappeared, although the tendon reflexes were still brisk (Fig. 2).

Case 2.—V.P., a male Eurafrican infant aged ten months, was admitted to hospital with a history of anorexia and diarrhoea for 14 days. Born as a normal full-time delivery, he was weaned on cow's milk at the age of three months. At five months he was started on thin maize porridge which usually contained some milk. On arrival in hospital the child was obviously malnourished. He weighed 9 lb. 2 oz. and showed evidence of mild nutritional oedema, hyperkeratotic nutritional dermatosis, atrophy and depigmentation of the scalp hair, cheilosis and marked muscular wasting. The abdomen was distended with gas, but the liver and the spleen were not enlarged.

The child was given a half-cream milk formula for two days and thereafter full-cream milk. Although the stool culture was negative for pathogens, the child was given 375 mg. of chloromycetin per day for the first seven days in hospital.

The child made an excellent recovery on this treatment, but 10 days after arrival in hospital it developed coarse tremors which involved the arms, the tongue,

the lips and the head as a whole. The face showed a vacant expression because the mouth of the child was hanging open, but there was no excessive salivation. The arms were held in an abnormal posture, being abducted at the shoulders and flexed at the elbows. Both thumbs were adducted into the palms.

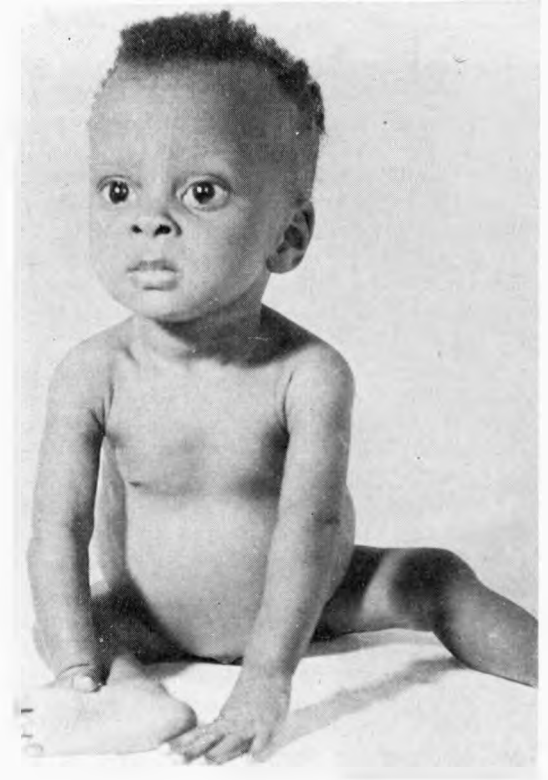

Fig. 2.—Case 1 six weeks later.

The legs showed no neurological abnormalities. There was no mental irritability or clouding of consciousness. The tendon reflexes were brisk. The child was able to sit up without support.

The neurological syndrome increased in intensity for the first two days. After two weeks a gradual improvement set in, and after a further 14 days the tremors were detectable only with difficulty, but the mouth was still kept open. Two months after the start, the neurological syndrome had cleared up entirely.

Case 3.—E.M., a female African child aged seven months, was admitted to hospital with diarrhoea and lobar pneumonia affecting the right upper and lower lobes. She was severely malnourished. Her hair was sparse, thin and straight and the skin was depigmented and dry. Her weight was 6 lb. 15 oz. The child had a poor feeding history. It had never been breast-fed. For the first three months of its life it received a mixture of one teaspoon of sweetened condensed milk in one cup of water three times a day. Thereafter the child was given a thin cereal gruel and one cup of milk daily. It remained on this diet until arrival in hospital.

The child recovered from the diarrhoea and the pneumonia. Ten days after admission she developed severe tremors of head and arms. The legs were not affected. The child was fully conscious. These neurological manifestations remained unchanged for a period of three weeks. Then a gradual improvement set in, and two months after admission to hospital there remained no trace of the syndrome.

DISCUSSION

The neurological manifestations in these three children were similar to those described previously in 16 other cases seen in Johannesburg (Kahn, 1954; Kahn and Falcke, 1956). After several months of faulty feeding with mixtures of cereals and water and little or no milk, the patients developed malnutrition and later diarrhoea. The diet was then changed to a milk mixture high in protein. The syndrome commenced seven to ten days after the change of diet had taken place.

As usual, extrapyramidal phenomena predominated in these children; there were tremors, cog-wheel rigidity, abnormal posture of arms and fingers and a sagging jaw. However, involvement of other parts of the central nervous system was indicated in Case 1 by exaggerated tendon reflexes, muscular weakness and myoclonus. All three children recovered completely within two months.

The cause of the syndrome is still obscure. Encephalitis can be excluded by persistently negative cerebrospinal fluid findings, invariable full recovery and constant relationship of the syndrome to the recovery phase of malnutrition. The syndrome is probably distinct from the portal-systemic encephalopathy described by Walsh (1951) and Sherlock *et al.* (1954) for reasons set out in detail elsewhere (Kahn and Falcke, 1956). Deficiency of vitamins A, D, C and B₁₂ and of nicotinamide, riboflavin, pyridoxin hydrochloride and pantothenic acid can be excluded as causes, because some of the children were receiving these substances when the tremors commenced. Administration of methionine and glutamic acid and the intravenous injection of glucose and calcium did not influence the course of the syndrome.

A large number of laboratory investigations have been carried out, all without gaining an insight into the disturbances underlying the neuropathy. Thus blood-urea, -sugar and -ammonia have been normal. Serum bilirubin, -phosphorus, -calcium, -sodium and -potassium have all been within normal limits. Urine specimens did not contain abnormal amounts of amino-acids. The stool cultures have not revealed any pathogens. A low protein diet given

over several days has failed to influence the tremors, and it has not been possible to attribute the syndrome to any particular drug.

Microscopic examination of liver sections of these cases has revealed only mild fatty changes. The electro-encephalogram has shown no abnormalities.

This neuropathy has been observed in other parts of the world where malnutrition is common in children. In Johannesburg all 19 cases originated in children under three years of age who were receiving treatment for malnutrition. However, all these patients had also been suffering from diarrhoea when dietetic treatment was instituted. Diarrhoea is common in advanced cases of malnutrition, and it is probably an integral part of the final metabolic breakdown. It is unlikely that the diarrhoea in these cases was infective in origin, because the severe type of infective diarrhoea occurs mainly during the summer period in Johannesburg, whereas these 19 cases were evenly distributed over the 12 months of the year.

It is almost certain that this syndrome is identical with the "acute cerebral tremors" described by Zappert (1909). His original paper indicates that the majority of the cases were malnourished. Despite this, he believed that the neurological manifestations were caused by infective processes such as measles, pneumonia, etc.

Zappert's term "acute cerebral tremors" is a misnomer, because the tremors form only one facet of the syndrome and they may already have disappeared while other components of the syndrome, such as postural abnormalities, are persisting. The eventual elucidation of the pathogenesis may lead to an appropriate name for the syndrome.

SUMMARY

Three cases are reported of a neurological syndrome related to the recovery phase of infantile malnutrition. The syndrome consists mainly of extra-pyramidal components, viz., tremors and postural abnormalities. Involvement of the pyramidal tract is slight and less constant. Complete recovery from the syndrome is the rule. A summary is given of the investigations undertaken to elucidate the cause of the syndrome.

REFERENCES

- KAHN, E. (1954). *Arch. Dis. Childh.*, 29, 256.
 ——— & FALCKE, H. C. (1956). *J. Pediatr.*, 49, 37.
 SHERLOCK, S., SUMMERSKILL, W. H. J., WHITE, I. P. and PHEAR, E. A. (1954). *Lancet*, 2, 453.
 WALSH, J. M. (1951). *Quart. J. Med.*, 20, 421.
 ZAPPERT, J. (1909). *Monatsschr. f. Kinderh.*, 8, 133.



This work is licensed under a
Creative Commons
Attribution – NonCommercial - NoDerivs 3.0 License.

To view a copy of the license please see:
<http://creativecommons.org/licenses/by-nc-nd/3.0/>

This is a download from the BLDS Digital Library on OpenDocs
<http://opendocs.ids.ac.uk/opendocs/>