

# The CENTRAL AFRICAN JOURNAL OF MEDICINE

Dr. DAVID LIVINGSTONE

Vol. 4, No. 9.

## CONTENTS

SEPTEMBER, 1958.

### ORIGINAL ARTICLES

Cardiac Disease of Obscure Origin	<i>M. Gelfand</i>	365
Baobab Tree as a Source of Vitamin C	<i>W. R. Carr</i>	372
Assessment of Muscular Hypertrophy and Endarteritis Obliterans in Pulmonary Arteries	<i>P. J. Barnard</i>	375
Portal Hypertension	<i>R. Milnes Walker</i>	378
Artificial Heart	<i>D. H. Thompson</i>	381
Acute Poliomyelitis in Europeans	<i>J. Melvin</i>	385
First School of Medicine in Southern Africa	<i>G. B. da Graca</i>	391
Diabetes Mellitus	<i>J. C. Shee</i>	392
The Untimely Demise of Dr. John Crotchet	<i>I. Anderson</i>	394

### EDITORIALS

Children in Hospital	395	Meeting of Orthopaedic Association	402
Hepatic Cirrhosis	396	Dr. Samuel Liptz	403
Diphtheria in the African	396	In Rhodesia Then	404
State Lotteries Grants for Doctors	397	Book Reviews	405
Session in S.R. Parliament	398	The Journal Library	408
Opening of New Childrens' Home, Salisbury	399	Salisbury Clinical Club	409
Opening of New Mpilo African Hospital	401	Latest Pharmaceuticals	410

PUBLISHED MONTHLY, ANNUAL SUBSCRIPTION £2 2s. 0d.

Registered at the General Post Office as a Newspaper.

# The Central African Journal of Medicine

Volume 4

SEPTEMBER, 1958

No. 9

## Cardiac Disease of Obscure Origin in Africa\*

BY

MICHAEL GELFAND, O.B.E., M.D., F.R.C.P.  
*Physician, Salisbury.*

Within recent years a number of papers have emanated from East, West, Central and South Africa, all reporting a form or forms of congestive heart failure, the etiology of which remains obscure. Interest in this subject began in 1946, when Bedford and Konstam published a series of 40 cases of unexplained heart disease in African troops, mostly from West Africa, serving in the Middle East.

There were earlier references in the literature to peculiar aspects of heart disease in Africans. Although the cause may have been incorrectly attributed, the fact remains that these men had the good sense and courage to publish their findings. For instance, Macfie and Ingram (1920) reported the occurrence of cardiac aneurysm of uncertain cause in the African of the West Coast, which occurred in either childhood or adult life. The aneurysm could be situated in an auricle, ventricle or in one of the heart valves. It not frequently ruptured with the supervention of sudden death. In other cases the heart failed gradually.

The next paper worthy of mention was that of Donnison, published in 1928. He recorded the findings in an African male aged 55 with cardiac failure accompanied by auricular fibrillation. The man died, and at autopsy hard, yellowish nodules were found in the left ventricle and both auricles. Donnison submitted the tissue for histological examination and the lesions were said to be gummata.

The most interesting contribution, perhaps, before that of Bedford and Konstam is one in 1938 by Williams (now Professor of Medicine

at the Mulago Medical School), and I believe that what he described was subendomyocardial fibrosis. He analysed 88 cases of cardiovascular syphilis, amongst which were two described as being syphilitic myocarditis. In both these cases the aorta and coronary arteries were normal. In one (a patient aged 40 with a positive Kahn reaction) Williams discovered at autopsy two large areas of fibrosis involving the whole thickness of the heart wall with a thrombus on the endocardial surface. These patches had not the sharply defined margins of an infarction. On histological examination the heart muscle at these sites was largely replaced by fibrous tissue. There was cellular infiltration chiefly by lymphoid cells, plasma cells and fibroblasts. Some of the arterioles showed perivascular cuffing with leucocytes. The second case was also in a man aged 40 in whom the aorta and coronary vessels were unaffected, but some aneurysmal dilatation was present at the apex of the heart. Cutting into the muscle revealed large serpigenous areas of firm whitish tissue distributed throughout most of the ventricular wall.

Prior to 1943 I had encountered in the Salisbury Native Hospital cases of heart failure which I could not readily explain. After eliminating conditions such as rheumatism, syphilitic valvular disease, hypertension, pericarditis and congenital disorders, beri-beri heart remained to be considered. Malnutrition was and still is prevalent in this kind of practice, so I tried doses of thiamine and even thyroid in case I was dealing with a subthyroid state, but these proved ineffective. Accordingly, in the first edition of the *Sick African*, published in 1943 (page 209), when dealing with the subject of beri-beri heart, I described these cases as follows: "One not infrequently sees a Native suffering from generalised oedema and congestive cardiac failure, which may be due to beri-beri. The signs found on cardiac examination point to a pericardial effusion which is confirmed by radiological examination of the chest. The condition often persists for weeks or even months. As a rule,

\* An address delivered to the Salisbury Cardiac Society on 26th October, 1957.

in spite of big doses of vitamin B therapy, no appreciable response to treatment can be seen. The vast majority leave hospital at their own request, their future progress being thus unknown. Those who remain mostly die. At *post-mortem* examination, congestion of the lungs and the liver, together with a pericardial effusion, is found, but no definite etiology can be given. In some of these men I have administered gradual doses of thyroid extract in case this condition was due to a subthyroid state, but such treatment has had little or no effect. It is tempting to diagnose all such cases in the Native, in whom deficiency disease is common, as being beri-beri heart. Some of these cases may, in fact, be due to the deficiency of the vitamin B complex, but I cannot believe that all are, as the response to treatment has been so disappointing." I was thus puzzled at that time with cases of congestive heart failure which I could not explain, but I failed to discover any characteristic pathological changes in the heart itself.

It was not until 1946, however, that Bedford and Konstam provided the first account of sub-endomyocardial fibrosis in the African. Indeed, before their article there were only a few references to this condition from America and Europe. But after their paper and that of Professor Davies of Uganda, who seems to have awakened universal interest in the disorder, the disease has been recorded from all over the world; and whilst the African appears particularly prone to it, it is not an altogether rare disease elsewhere, including Britain.

It is worth mentioning Bedford and Konstam's article in a little more detail. They found at autopsy in some of their cases an obvious sub-endocardial fibrosis with fibrotic patches resembling shallowish infarcts in the ventricles to which organised ante-mortem clots were adherent. On histological examination, extensive sub-endocardial necrosis and fibrosis without appreciable inflammatory reaction was observed. In the clinical examination they noticed that the diastolic pressure was relatively high—usually in the vicinity of 100 mm. Hg. They were unable to explain the fibrosis and suggested that it might be similar to that of isolated myocarditis (Fiedler's myocarditis). They doubted whether the disease was nutritional, as the diet of the soldiers was good. Thiamine therapy was of no avail.

Soon afterwards Professor Davies, of the Uganda Medical School, gave a very clear description of subendomyocardial fibrosis as seen

by him. Since then he and some of his colleagues in Kampala have published further interesting observations on this condition. In 1948, Davies estimated that nearly 10 per cent. of cases of congestive heart failure were of this variety. The chief features recorded by him were the frequency of valvular incompetence, the frequent presence of a pericardial effusion and a large globular-shaped heart. On opening the heart he found that the endocardium, usually at the apex of the left ventricle, was thick, of a pearly-white colour, with strands of fibrous tissue passing down into the depths of the myocardium. The endocardial fibrosis extended upwards from the apical region into the ventricular wall engulfing the papillary muscles and causing thickening and even fusion of the chordae tendinae. As a result, the mitral valve was pulled down and distorted, presenting a funnelled appearance resembling that found in mitral stenosis. Rarely was another valve affected. Out of 229 Africans suffering from congestive cardiac failure, Davies found 9.6 per cent. with endocardial fibrosis and in another 5 per cent. no cause could be found for the heart failure. In this paper Davies referred to another little-understood cardiac disorder in which the myocardium was infiltrated by small found cells.

In 1954, Davies, Williams and Ball contributed further to the pathology of endomyocardial fibrosis and provided more interesting findings on the disease. They showed the presence of both dilatation and hypertrophy in the ventricles and that the pericardium and epicardial muscle remained healthy. The endocardial fibrosis, they observed, might be confined to small patches or it might involve almost the whole of one or both ventricles. The fibrous layer might be several millimetres thick, extending as far as two-thirds of its thickness into the myocardium. The papillary muscles might be surrounded by fibrous tissue and the chordae tendinae thickened, fused and shortened. The cusps were often fibrosed and attached to adjacent structures, the posterior mitral cusp being particularly liable to be involved in the process and fixed to the posterior wall. Further, the mitral or tricuspid valve might be attacked, leading not uncommonly to mitral or tricuspid incompetence. The most frequent lesion in the auricle was the ante-mortem thrombus in the appendages and which might become converted into fibrous tissue. Embolic lesions are very rarely seen in Uganda. The authors recorded for the first time that the right ventricular lesion differed from the left in that the advancing fibrosis invariably produced an obliteration of the cavity in the

region of the apex. This led to increased pressure in the cervical veins, hepatic enlargement, oedema and ascites. Davies and his colleagues had little to add on the microscopy. They stressed firstly a superimposed (endocardial) layer of hyaline, avascular fibrous tissue and a deeper one with dilated blood vessels, with at times an increase of elastic fibres. The muscle fibres showed hydropic, hyaline or waxy degeneration, often with enlarged hyperchromatic nuclei.

In Uganda no age group was exempt and both sexes were equally affected. Because of the main lesions in endomyocardial fibrosis, Davies *et al.* considered that there were four main clinical effects of the disease. These might be seen singly or in almost any combination. They were:—

- (1) Endo- and myocardial fibrosis leading to left ventricular enlargement.
- (2) Mitral incompetence.
- (3) Tricuspid incompetence.
- (4) Obliterative fibrosis of the right ventricle.

The most frequent feature was congestive heart failure with or without mitral incompetence. They summarised the chief signs as follows:—

- (1) A loud apical systolic murmur.
- (2) Heart failure without other distinguishing features.
- (3) Enlargement of the left auricle in the absence of mitral stenosis.
- (4) Tricuspid incompetence in the absence of bacterial or rheumatic heart disease.
- (5) Signs suggestive of constrictive pericarditis.
- (6) A large hydropericardium of unexplained origin.

The E.C.G. changes were non-specific, being mainly low, flat or inverted T waves, low voltage QRS in the limb leads, and sometimes a right or left ventricular strain with QRS splintered and broad. A few showed incomplete bundle branch block.

The prognosis in most cases appeared to be poor and lingered for weeks or months in a water-logged condition. They found the response to mercurials, digitalis and diuretics disappointing. Others after some improvement quickly relapsed. The authors came to the conclusion that "It seems that once heart failure is established in endomyocardial fibrosis, there is little chance of remission or of controlling failure sufficiently to expect any useful capacity for sedentary activity."

Another paper that deserves mention is one by Gray (1951), who described the disease in two Europeans living in West Africa. The first case was a doctor who had lived in Nigeria for

nine years and had contracted loa-loa. He developed attacks of dyspnoea and cough and returned to England, where he died the following year. At autopsy, endocardial fibrosis was found at the apex as well as a hypertrophied right ventricle, and the lower two-thirds of the left ventricle was lined with fibrous tissue. The marginal cusp of the mitral valves was slightly adherent to the ventricular wall. The second patient, a magistrate of 36, also probably affected with loa-loa, died of congestive cardiac failure. At autopsy the cavities of the ventricles were almost filled with tough organising thrombus, firmly bound down to the endocardium. The cut surface of the ventricular wall showed marked organisation of the thrombus. Its inner half was whitish in colour, with fibrous tissue spreading into it from the thick fibrous endocardium. The histological features were typical of the disease.

By 1951 the Johannesburg school began to take up the subject of obscure heart disease seriously. The first in the field was Gillanders, who recorded in the *British Heart Journal* a form of congestive heart failure believed not to have been previously described in African adults. The outstanding clinical features he described were:—

- (1) Enlargement of the whole heart, which on fluoroscopy was typically inert.
- (2) The constancy of a gallop rhythm.
- (3) The extreme degree of oedema.
- (4) The co-existence of cirrhosis of the liver.

At autopsy no important changes were observed in the heart muscles, valves or coronary vessels, no convincing evidence of cardiac fibrosis, nor was the amount "of pericardial fluid significant from the point of view of producing either this clinical syndrome or the radiological appearance of the heart." Microscopically he found only interfibrillary oedema of the myocardium. The diet of all his cases was deficient, and of special significance was that in all but those in the most advanced stages of the disease the heart diminished in size and signs of failure lessened when a well-balanced diet was given. He mentioned, however, that this syndrome of heart failure did not clinically resemble beri-beri.

The following year Higginson, Gillanders and Murray published another paper in the *British Heart Journal* based largely on what he had written in the first. They failed to find the severe fibrosis in the subendocardium described by Davies and believed the disorder to be the result of chronic malnutrition. In all their 12 cases the hearts were dilated and hypertrophied,




Fig. 1—Thrombus on inner surface of heart undergoing hyalinisation.

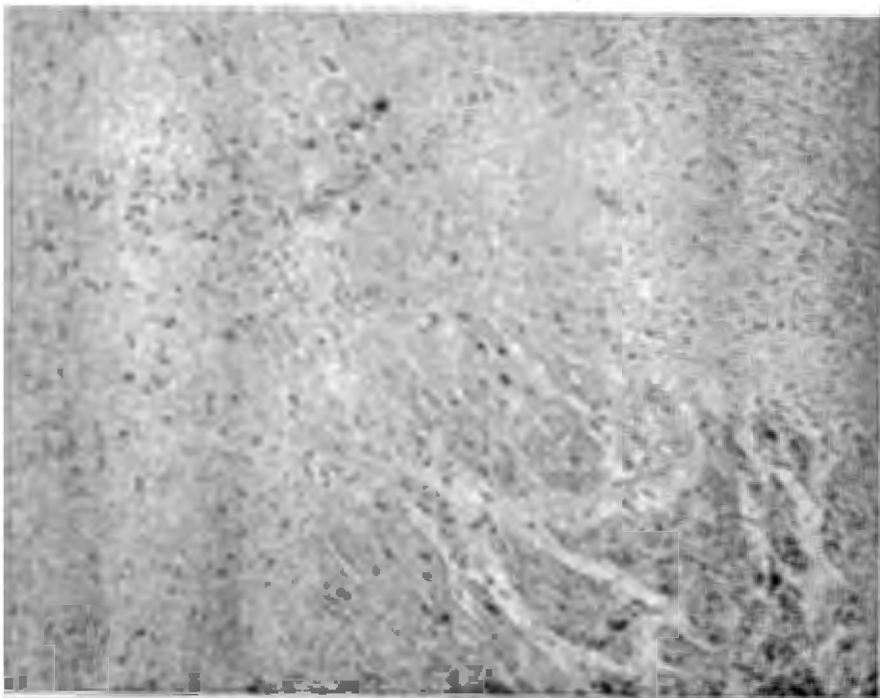


Fig. 2—The extent of the fibrous tissue which has infiltrated into the myocardium is clearly seen.

but other myocardial lesions were inconspicuous except in four cases in whom foci of scarring was found. Endocardial mural thrombi were demonstrated in about half the cases and peripheral emboli were frequent. The thrombi were organised to a varying extent, but the underlying myocardium was normal except for focal scarring and interstitial fibrosis. In the four cases with scarring the fibrous areas were up to 2 sq. mm. and small foci of leucocytes were detected infiltrating between the muscle fibres.

To complicate the picture, Becker, Chadgikakis and van Lingen, also from Johannesburg, described in 1953 what might appear yet another cardiopathy, but seemed to have certain features similar to the endomyocardial fibrosis and heart failure recorded by Gillanders and his colleagues. This they have named *cardiovascular collagenosis with parietal endocardial thrombosis*.

The heart failure was of a fairly rapid, progressive type, lasting about six months, but death might supervene from within a month to three years from the time the patient was first seen. Becker's description was based mainly on the histological changes. The earliest lesions he found consisted of swelling of the endothelium—mucoid oedema—followed by an increased permeability of the endotheloid cells. Fibrin exuded on to the endocardial surface and in time was followed by a mural thrombus which underwent organisation. At the same time, sub-endocardial necrosis developed as a result of the mucoid oedema. A severe myocarditis occurred with myocardial oedema, separation of the muscle bundles and degeneration of the muscle fibres themselves. These changes were found mostly in the inner third of the myocardium. The degeneration of the myocardium included necrobiosis, nuclear disintegration of the fibres as well as foci of eosinophilic infiltration.

In Becker's cases the essential feature was a fibro-elastosis which was never severe and consisted of small endocardial plaques, usually found at the apex of the heart, in the papillary muscles, on the outflow tract of the heart, in the upper part of the interventricular septum and in the auricles. It was exceptional in Johannesburg to encounter the types recorded by Davies and his colleagues in Uganda. Becker also stressed that the cardiopathy described by him was seen in Europeans as well, and he had no reason to believe it was due to a lack in one of the food elements or even to a virus.

A recent publication worthy of mention is one by Altmann and Stein (1956), of Johannesburg.

They described four cases of idiopathic cardiac hypertrophy in African children, but in none was there a distinct congenital anomaly or a known cause of cardiovascular disease. The authors excluded acute isolated myocarditis (Fiedler's myocarditis, interstitial myocarditis), anomalous origins of left coronary artery from the pulmonary artery, glycogen storage disease (von Girke's disease), endocardial fibroelastosis and rhabdomyoma.

Clinically their cases closely resembled Gillander's "nutritional heart disease," i.e., hypokinetic circulation, poor movement of the heart and unsatisfactory response to treatment, but there was no evidence of malnutrition in their patients. The ages of the children were six years, four years, two years and 15 months. At autopsy all the chambers of the heart were dilated and hypertrophied. Histologically they found hypertrophy of the muscle fibres with slight cellular infiltration of the myocardium and slight fibro-elastic thickening of the endocardium. An ante-mortem thrombus was attached to the endocardium of the left ventricle.

After studying Altmann and Stein's paper I find no good reason for separating their cases from those already described from Johannesburg, and the fact that they failed to demonstrate signs of malnutrition does not, in my opinion, warrant the claim of their cases being a separate entity.

#### THE PICTURE IN MASHONALAND

As already pointed out, we were aware as long ago as 1943 that we were encountering cases of obscure cardiac failure and we now know more of its pathology, thanks to the work of Davies and Becker. The cause is still unknown and we are not certain whether the more fibrotic lesions seen by Davies of Uganda are similar to those recorded in South Africa. The clinical picture of both conditions is very similar and I do not believe one can foretell during life what type of heart disease one will find at autopsy. The prognosis of both types seems to be bad, although perhaps the form of heart failure in the more southern parts is less severe than that occurring in Uganda. Pathologically the cases I have been able to study at autopsy correspond more to those described by Gillanders, Becker and their colleagues. Indeed, at autopsy one sees little abnormality in the chambers of the heart, the endocardium and myocardium appearing, for all practical purposes, normal. In some, however, there is an ante-mortem clot of extensive degree, especially

in one of the auricular appendages or at the apex of the left ventricle. In those areas, whether or not there is a thrombus, the endocardium appears whitish and opaque in patches and the myocardium underneath is paler than the rest of the myocardium. The same paler areas are seen in the papillary muscles. The valves are unaffected. Not infrequently a slight or moderate pericardial effusion is found, but the pericardial sac is not itself obviously involved.

Idiopathic or obscure heart disease is common in African practice, accounting for about 15 per cent. of my cases seen with a cardiac disorder (Gelfand, 1952).

An interesting feature of this form of heart failure is that despite the frequent formation of a thrombus, embolic phenomena are rarely seen. I do not know the reason for this. Recently, however, I published a case in which emboli caused gangrene in the extremities (Gelfand, 1957).

I have noticed that this form of heart failure is not uncommonly developed by women who have recently given birth. In the African whose diet is poor one would expect the heart failure at this stage in her life to be due to some nutritional deficiency, but courses in thiamine, nicotinic acid and proteins have not been successful in effecting a cure.

Not infrequently I find a slightly or moderately enlarged heart, confirmed radiologically, in a young African admitted to hospital for a different condition, such as malaria, hookworm disease or bilharziasis. The patient has no complaint referable to his heart; there are no murmurs to be heard, no abnormalities in the size of the heart or in the blood pressure are noticed, and the E.C.G. is normal. I do not know the reason for this, but I have often wondered whether some of these cases do not later develop the fully fledged picture of congestive cardiac failure.

I would thus classify my cases of obscure heart disease in the African into the following clinical types:—

- (1) Typical congestive cardiac failure in male or female adult.
- (2) Congestive cardiac failure in a woman who has recently been delivered of an infant.
- (3) Cardiac failure in infants and children.
- (4) Pericardial effusion of slight or moderate degree.
- (5) Enlargement of the heart in young males or females in excellent health as regards their cardiac capacity.

But as pointed out by Gray and Becker, both endomyocardial fibrosis and fibroelastosis of the heart of obscure origin can occur in the European, and this may not be altogether rare. I must admit that in the vast majority of Europeans with heart failure a cause can be found, but occasionally one is encountered in which no cause is evident. It might be of interest, therefore, to record the findings in a European female who died recently of cardiac failure which commenced after she had given birth to an infant. She was attended by Dr. Liptz, Dr. Bernberg and myself in the Lady Chancellor Home and then in the General Hospital, and we were able to follow her closely until her death three months later.

The patient was 40 years old and had a child of 19 years. She was very pleased when she fell pregnant again, although she realised she was a little old for the pregnancy and the eventual labour. During the early part of the pregnancy she was admitted to St. Anne's because of hyperemesis. Otherwise she was fairly well during the pregnancy, with no evidence of having had signs of heart disease.

She was admitted to the Lady Chancellor Home on 17th January, with the baby in the R.O.A. position. The foetal heart was heard. There was a normal delivery that evening of a living female infant, and the third stage was uneventful.

About 12 hours after the birth of the baby she suddenly collapsed. No bleeding was noted and there was no pain in any part of the body. The pulse was rapid—132 per minute—of poor volume, regular, and the blood pressure was first recorded as being 100/80. Nothing abnormal was noted in the abdomen. The apex beat of the heart was of a heaving type, but the sounds were closed. It was thought that she had paroxysmal tachycardia. A cardiograph showed a sinus tachycardia with the inversion of T<sub>1</sub>, T<sub>2</sub>, T<sub>v4</sub> and T<sub>v5</sub> and a left ventricular preponderance. Her collapse became very much worse, and after a few hours it was decided to administer a drip saline as her blood pressure was not recordable. A blood count showed a haemoglobin of over 80 per cent. and a blood urea of 40 mg. per cent. It was necessary to continue the saline for about six days, by which time she had improved a great deal. But as both her legs were markedly swollen, it was decided to stop it. She was then also showing signs of congestive heart failure. The neck veins were moderately distended, the liver enlarged and tender, and we decided to give her mercurials as well as digoxin and thiamine. Her pressure had returned to normal levels and she gradually improved and was much happier in herself. But the convalescence was very slow, and after about six weeks it became necessary to transfer her to the General Hospital.

The heart was moderately enlarged, mostly of a left ventricular type, and by this time there was a marked systolic bruit at the apex. The swelling of her legs persisted, and it was clear that she had a thrombosis in both her femoral veins. Her pulse too at times became irregular due to multiple ventricular extra systoles. She was orthopnoeic all the time. The breathlessness never left her and she was unable to lie flat in bed. She suddenly died in April—three months after the commencement of the illness. By then we

considered the most likely diagnosis to be subendocardial fibrosis of the heart, and this was confirmed at an autopsy conducted by Dr. Douglas Ross.

At the *post-mortem* examination all the chambers of the heart were found to be enlarged, especially the left ventricle, which also showed an extensive mural thrombus, beneath which was a diffuse zone of subendocardial fibrosis. Two portions of tissue were taken from this area of the left ventricle. The sections showed a subendocardial fibrosis (Figs. I and II) with an attached mural thrombus. Dr. Ross reported as follows: "It would appear that the fundamental cause of death in this case must be traced to the subendocardial fibrosis, with possible interruption of the heart stimuli." He also found that the uterine cavity contained purulent contents. On section it revealed that this was composed of a hyaline thrombus adherent to the endometrial wall, there being only mild inflammatory changes. And he added, "I think the condition of the uterus and pelvic veins represent but incidental findings."

#### CONCLUSION

Throughout East, West, Central and South Africa a peculiar and common form of heart failure is seen. Perhaps it would be preferable to say forms instead of form, as we already know that the extent of the lesions in the more northern regions of Africa are more extensive than those seen in the south; but no matter where the disorder is encountered, the prognosis is poor. Whether the types are the same or what the cause is remains at present unanswered. In both types, however, thrombus formation is found.

The condition is common in Africans, but in the European the disease has been described and may be commoner than is generally believed. It should be considered more often in the differential diagnosis of congestive cardiac failure.

#### SUMMARY

(1) The literature on subendomyocardial fibrosis and idiopathic heart failure in Africa is reviewed.

(2) The clinical picture of idiopathic heart failure in Mashonaland is described.

(3) A European female aged 40 died in Salisbury of subendomyocardial failure and the findings are recorded.

#### REFERENCES

- ALTMAN, H. & STEIN, H. (1956). *Brit. med. J.*, 1, 1207.  
 BALL, J. D., WILLIAMS, A. W. & DAVIES, J. N. P. (1954). *Lancet*, 1, 1049.  
 BECKER, B. J. P., CHADGIDAKIS, L. B. & VAN LINGEN, B. (1953). *Circulation*, 7, 345.  
 BEDFORD, D. E. & KONSTAM, G. L. S. (1946). *Brit. Heart J.*, 8, 236.  
 DAVIES, J. N. P. (1948). *E. Afr. med. J.*, 25, 10.  
 DONNISON, C. P. (1928). *Ken. med. J.*, 5, 48.  
 GELFAND, M. (1943). *The Sick African*, Steward Printing Co., Cape Town. First Edition, p. 209.  
 GELFAND, M. (1952). *West. Afr. med. J.*, 1, No. 3, 1.  
 GELFAND, M. (1957). *Cent. Afr. med. J.*, 3, 374.  
 GILLANDERS, A. D. (1951). *Brit. Heart J.*, 13, 177.  
 GRAY, I. R. (1951). *Brit. Heart J.*, 13, 387.  
 HIGGINSON, J., GILLANDERS, A. D. & MURRAY, J. F. (1952). *Brit. Heart J.*, 14, 213.  
 MACFIE, J. W. S. & INGRAM, A. (1920). *Ann. trop. Med. & Parasit.*, 14, 147.  
 WILLIAMS, A. W. (1938). *Ken. med. J.*, 15, 279.  
 WILLIAMS, A. W., BALL, J. D. & DAVIES, J. N. P. (1954). *Trans. Roy. Soc. trop. Med. & Hyg.*, 45, 290.

#### Acknowledgments

I wish to thank Dr. Douglas Ross, Government Pathologist, for the autopsy and histological findings on the case presented in this paper and Dr. D. M. Blair, O.B.E., for permission to publish this address.





This work is licensed under a  
Creative Commons  
Attribution – NonCommercial - NoDerivs 3.0 License.

To view a copy of the license please see:  
<http://creativecommons.org/licenses/by-nc-nd/3.0/>

This is a download from the BLDS Digital Library on OpenDocs  
<http://opendocs.ids.ac.uk/opendocs/>