

# The Central African Journal of Medicine



*Editor:*

MICHAEL GELFAND, C.B.E., M.D., F.R.C.P.

*Assistant Editor:*

JOSEPH RITCHKEN, M.D.

---

**Volume Nineteen**  
**JANUARY - DECEMBER**  
**1973**

---

LIBRARY

*Handwritten signature or initials*

SALISBURY

RHODESIA

*Handwritten text: CENT IV*

# The Central African Journal of Medicine

Volume 19

SEPTEMBER, 1973

No. 9

## Pancreatic Calcification in Rhodesian Africans

BY

A. C. B. WICKS

Lecturer in Medicine, University of Rhodesia

### INTRODUCTION

Pancreatic calcification in Africans has been well documented from Nigeria (Kinneer, 1963; Olurin & Olurin, 1969), Uganda (Shaper, 1964) and the Congo Republic (Sonnet, Brisbois & Bastin, 1966). However, only one case report has been described from Rhodesia (Gelfand & Carr, 1961), Malawi (Goodall & Pilbeam, 1964) and Tanzania (Haddock, 1964). (Fig. 1).

During a one year period, October 1970 to September 1971, all new diabetic patients admitted to Harari Hospital were screened for

steatorrhoea and had an X-ray of their abdomen for pancreatic calcification. Of 98 patients X-rayed, three were found to have pancreatic calcification. During the same period of study two other patients were also seen with pancreatic calcification, one had been a diabetic for three years and the other a new diabetic who died soon after admission, and was found at autopsy to have extensive pancreatic calcification.

In addition to the above five cases, two other patients have been seen at Harari Hospital with pancreatic calcification, one in 1966 and the other in 1973. This communication describes the clinical pattern seen in these seven patients, with a brief review of the aetiology and clinical description as found elsewhere on the African continent.

### CASE HISTORIES

#### Case 1

C.M. 41 year old male waiter.

*History:* Classical history of diabetes with polyuria, polydipsia and loss of weight. Large bulky foul smelling stools for 2 years. No abdominal pain before admission.

*Past history:* Ten years previously severe attack of acute abdominal pain with radiation through to back. No operation performed. Heavy drinker of African home brewed beer.

*Examination:* Well built man with parotid enlargement. No neuropathy or retinopathy.

*Relevant Investigations:* Haemoglobin 15 grams/100 ml. Glucose Tolerance test (G.T.T.) diabetic curve. D-Xylose and vitamin B<sub>12</sub> absorption normal. Faecal fat excretion 13.6 grams a day. Jejunal biopsy slightly abnormal with mainly leaf villi and numerous ridges. Abdominal X-ray—pancreatic calcification. Pancreatic function test (P.F.T.), grossly abnormal. Duodenal loop elongated and irregular. (Fig. 2).

*Treatment:* 60 units of Lente insulin daily.

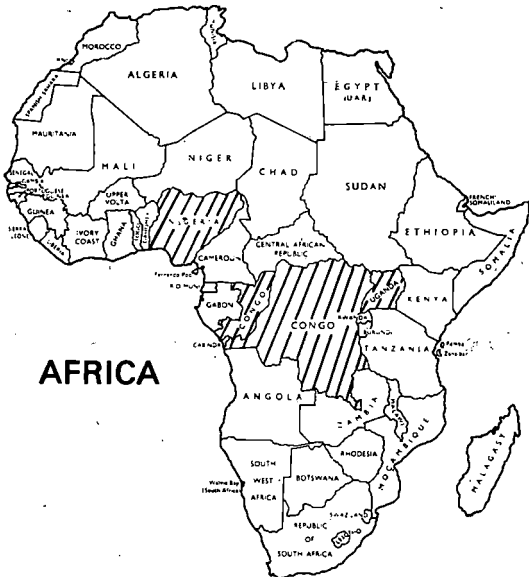


Fig. 1.—Lined areas indicate where pancreatic calcification has been described in African patients.

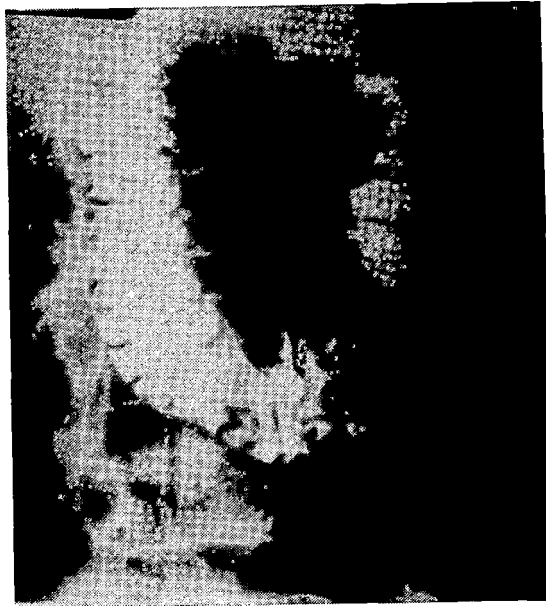

Fig. 2.—Elongated duodenal loop with small flecks of calcification visible in loop.

Case 2

A.M. 44 year old male cashier.

*History:* Vomiting and upper abdominal pain for two weeks, no radiation through to back. Classical symptoms of diabetes mellitus on direct questioning.

*Past History:* Nine months previously acute attack of abdominal pain necessitating hospital admission. No operation performed. Diagnosed as peptic ulceration with little proof; in retrospect almost certainly acute pancreatitis. Heavy drinker of home brewed African beer.

*Examination:* Thin man with epigastric tenderness. No parotid or liver enlargement, retinopathy or neuropathy.

*Investigations:* Haemoglobin 12 grams/100 ml. G.T.T. diabetic curve. Bilirubin 1,8 mgs./100 ml. Alkaline phosphates 32 K.A. units/100 ml. S.G.O.T. and S.G.P.T. normal. Albumin 3,5 grams/100 ml. No serum insulin response to I.V. tolbutamide. Faecal fat excretion 7,6 grams a day. D-xylose and B<sub>12</sub> absorption normal. Pancreatic Calcification on abdominal X-ray. Hypotonic duodenography showed obstruction in second part of duodenum. (Fig. 3). P.F.T. grossly abnormal. Jejunal biopsy was abnormal with predominantly convolutions and stunted villi.

Laparotomy (Mr. J. Gordon): Carried out for symptoms of obstruction and jaundice, showed a large retroperitoneal abscess with granulation tissue causing obstruction to second part of duodenum.

*Treatment:* Chlorpropamide 500 mgs. daily.

Case 3

M. H. 40 year old municipal policeman.

*History:* Intermittent abdominal pain with radiation through to back over a three year period. Jaundice noticed one week before admission. No history to suggest steatorrhoea. No past episodes of severe abdominal pain. Heavy drinker of home brewed African beer.

*Examination:* Haemoglobin 14 grams/100 ml. G.T.T. diabetic curve. A good serum insulin response to I.V. tolbutamide. Bilirubin 2,9 mg. %, alkaline phosphatase 40 K.A. units/100 ml. S.G.O.T. 36 IU/ litre. S.G.P.T. 51 IU /litre. Serum albumin 3,1 grams/100 ml. D-xylose excretion and vitamin B<sub>12</sub> absorption normal. Faecal fat excretion 11,4 grams a day. Jejunal biopsy abnormal with a predominantly ridged pattern with a few stunted leaf villi (Fig. 4). Duodenal loop very irregular. P.F.T. grossly abnormal. Abdominal X-ray — Pancreatic Calcification.



Fig. 3.—Obstruction of second part of duodenum in Case 2 with a trickle of barium leaking through. Air outlines stomach with duodenal tube in position.



3, 4.—Jejunal biopsy showing predominantly ridged pattern with a few stunted leaf villi in Case 3.

*Laparotomy* (Mr. S. Wapnick) performed because of obstructive jaundice; enlarged head and body of pancreas found suggestive of carcinoma. A by-pass procedure was performed and the biopsy showed chronic pancreatitis with no evidence of malignancy.

*Case 4*

W.M. 36 year old male storekeeper.

*History:* Three years before admission diagnosed at laparotomy as acute pancreatitis. Since then poorly controlled diabetes; admitted for stabilisation. Occasional episodes of central abdominal pain and foul smelling yellow stools. Was a heavy drinker of home brewed African beer.

*Examination:* Thin man with no retinopathy, neuropathy or parotid enlargement.

*Investigations:* Haemoglobin 13 grams/100 ml. Albumin 2,4 grams/100 ml. Faecal fat excretion 16 grams a day. Abdominal X-ray —pancreatic calcification. Duodenal loop elongated and irregular. P.F.T. grossly abnormal.

*Treatment:* Controlled on Lente insulin 25 units daily.

*Case 5*

K.K. 62 year old farm labourer.

*History:* Classical history of diabetes mellitus. No abdominal pain or previous history of serious illness. Initial blood sugar 515 mgs./100 ml. One day after admission began to twitch on one side of the body and later lapsed into coma.

Not hypoglycaemic. Died one day later and autopsy revealed an extensively calcified fibrotic pancreas (Fig. 5) with heavy deposits of haemosiderin in the hepatic and Kupffer cells and portal areas. No explanation found for sudden deterioration and death.

*Case 6*

M.M. Housewife aged 40.

*History:* Three weeks right sided abdominal swelling with an 8 month history of intermittent central and epigastric pain without radiation to back; loss of weight. Jaundice noticed one week before admission. No previous history of severe abdominal pain. Was a heavy drinker of home brewed African beer.

*Examination:* Thin jaundiced woman with a palpable liver, gall bladder and epigastric mass. No parotid enlargement.

*Investigations:* Haemoglobin 12,6 grams/100 ml. Bilirubin 26,4 mgs./100 ml. (Conjugated 17,4 mgs./100 ml.) S.G.O.T. 100 IU/litre, S.G.P.T. 65 IU/litre. Alkaline phosphatase 41 K.A. units/100 ml. Albumin 2,7 grams/100 ml. G.T.T. not diabetic. Straight X-ray of abdomen — pancreatic calcification (Fig. 6).

*Laparotomy* (Mr. Fleming): Performed because of obstructive jaundice. An enlarged firm pancreas with calcified and cystic areas was found with a distended common bile duct (C.B.D.) and an enlarged cirrhotic looking liver. Duodenostomy was performed and a stenotic area found in the C.B.D. within the pancreatic head. Duodeno-cholecystostomy was done and a biopsy from the pancreatic duct and from a cyst showed a well differentiated adenocarcinoma of duct origin.

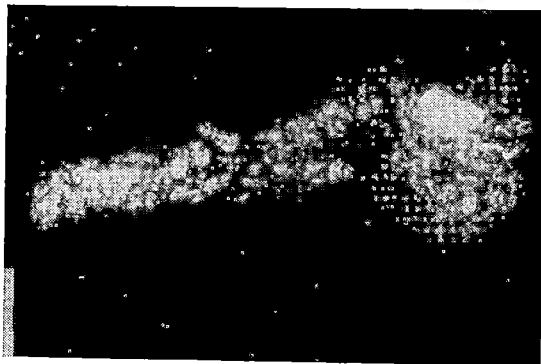


Fig. 5.—Post mortem X-ray of the pancreas showing extensive calcification of the pancreas in patient 5.

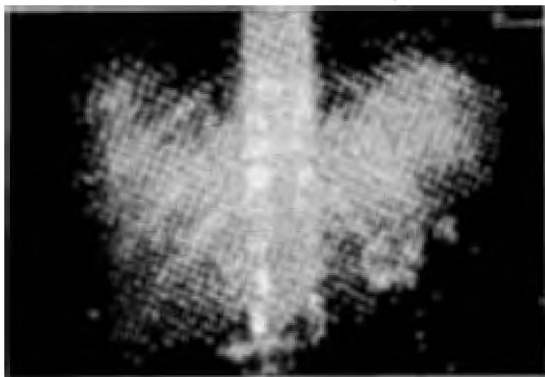


Fig. 6.—Extensive pancreatic calcification seen in straight X-ray of abdomen in Case 6.

### Case 7

D.A. 12 year old school girl.

*History:* Classical symptoms of diabetes mellitus. No abdominal pain.

*Investigations:* (Dr. Clain) Initial blood sugar 1000 mgs./100 ml. Haemoglobin 11.2 grams/100 ml. Faecal fat excretion 10.6 grams a day. Abdominal X-ray—pancreatic calcification. D-xylose excretion and B<sub>12</sub> absorption normal. Jejunal biopsy within normal limits.

*Treatment:* 120 units of soluble insulin in divided doses; control very difficult.

### DISCUSSION

Pancreatic calcification is much more common in Rhodesian Africans than was hitherto thought. Five cases were seen during a one year study period, emphasising the point that the more diligently one looks for a condition the more cases will be found.

A number of common clinical features became apparent from this small series. Most of the patients were male, who were over the age of 40 and were heavy drinkers of home brewed beer. No patients drank spirits. Three patients gave a history of either proven (or suggestive of) acute pancreatitis prior to the discovery of their pancreatic calcification. Two patients denied any history of abdominal pain and only two on direct questioning had a history suggestive of steatorrhoea. No patients had a family history of diabetes. Three patients presented with jaundice and only one had parotid enlargement. No patients were anaemic. Six of the patients were diabetic and all five patients who had faecal fat excretion measured had steatorrhoea (in excess of 6 grams of fat a day).

When the clinical picture of pancreatic calcification is compared with pancreatic calcifi-

cation in temperate climes, the most striking difference is the greater incidence seen in African patients of associated steatorrhoea and diabetes.

*Aetiology:* There has been much discussion on the Aetiology of pancreatic calcification of the African continent.

*Alcohol:* In France (Sarles et al., 1965), the U.S.A. (Howard & Jordan, 1960), the U.K. (Howat, 1968) and in the Cape Coloured population in Cape Town (Marks & Bank, 1965) alcohol appears to be aetiologically significant in chronic pancreatitis. In Africa the cause is less clear. Olurin & Olurin (1969) in Nigeria categorically state that alcohol does not play a roll in the aetiology as 75 per cent. of the patients are under the age of 20. Shaper (1964) in Uganda feels that there are a number of factors interacting on the pancreas, alcohol being one, in patients who are generally poorly nourished. Six of the seven patients reported here were heavy drinkers of African beer and obviously the aetiology in the little girl must be completely different.

*Malnutrition:* This appears to be aetiological role favoured by most African writers (Kinnear, 1963; Shaper, 1964; Sonnet *et al.* 1966; Olurin & Olurin, 1969). However, the objective proof for this is scanty as there has been no long term prospective study of patients from a malnourished childhood to adulthood. The problems of such a study are obviously enormous. However, there is some evidence from pancreatic function tests (P.F.T.). Barbezat (1967) in Cape Town demonstrated that exocrine pancreatic function returns to normal in children with kwashiorkor who are successfully treated, but that in the more chronically malnourished children the P.F.T. does not return to normal following dietary treatment. Further support comes from Uganda where Banwell & Campbell (1967) investigated seven patients with protein caloric malnutrition. Following dietary treatment two of these patients were re-investigated with a P.F.T. which was still found to be abnormal, indicating permanent pancreatic damage.

Other possibilities have been put forward, such as acute pancreatitis, but as in other countries (Uganda, Shaper 1960; Banwell et al., 1967; Nigeria, Olurin & Olurin, 1969) acute pancreatitis is rare in Rhodesia. Only 20 cases have been documented over a three year period at Harari Hospital (Wicks & Fleming, 1973), but three of the patients in this series gave a history of such an attack.

Gallstones and biliary stones are also very uncommonly encountered (Wicks, Holmes & Davidson, 1971) at Harari Hospital and appeared to play no obvious aetiological roll.

There have been a few case reports of pancreatic schistosomiasis with diabetes (Olurin & Olurin, 1969; Bibawi, 1970) but autopsy findings at Harari Hospital on diabetics have not suggested this association here.

The possible part played by African herbs and medicine is purely conjectural but probably warrants further investigation.

#### SUMMARY

Seven patients with pancreatic calcification are presented. Three of these patients gave a history of acute pancreatitis and six were heavy drinkers of African beer. Five of the patients investigated had steatorrhoea and six were diabetic. The possible aetiological factors and a brief review of pancreatic calcification in Africans are discussed.

#### ACKNOWLEDGMENTS

I would like to thank Mr. Gordon, Mr. Fleming and Mr. Wapnick for giving me permission to report their cases. Professor J. J. Jones kindly estimated the serum insulin levels. Mr. D. R. Barley and the staff of the Records Department were as helpful as ever.

This work forms part of a thesis for the M.D. (Birmingham) and was made possible by a generous research grant from the University of Rhodesia.

#### REFERENCES

- BANWELL, J. G., HUTT, M. S. R., LEONARD, P. J., BLACKMAN, V., CONNER, D. W., MARSDEN, P. D. AND CAMPBELL, J. (1967). *GUT* 8, 388.
- BARBEZAT, G. O. (1967) *S.Afr.med.J.* 41, 84.
- GELFAND, M. AND CARR, W. R. (1961) *C.Afr.J.med.* 7, 41.
- GOODALL, J. W. D. AND PILBEAM, S. T. H. H. (1964) *Trans. Roy. Soc. trop. Med. Hyg.* 58, 575.
- HADDOCK, D. R. W. (1964) *E.Afr.med.J.* 41, 145.
- HOWARD, J. M. AND JORDAN, G. L. (1960) "Surgical diseases of the pancreas", Lippincott, Philadelphia, p. 203.
- HOWAT, H. T. (1968) *Postgrad. med. J.* 44, 733.
- KINNEAR, T. W. G. (1963) *E.Afr.med.J.* 40, 288.
- MARKS, I. N. AND BANK, S. (1963) *S.Afr.med.J.* 37, 1039.
- OLURIN, E. O. AND OLURIN, O. (1969) *Brit.med.J.* IV 534.
- SARLES, H., SARLES, J. C., CAMATTE, R., MURATORE, R., GAINI, M., GUIEN, C., PASTOR, J. AND LEROY, F. (1965) *GUT* 6, 545.
- SHAPER, A. G. (1960) *Lancet* 1, 1223.
- SHAPER, A. G. (1964) *Brit.med.J.* 1, 1607.
- SONNET, J., BRISBOIS, P. AND BASTIN, J. P. (1966) *Trop. Geog. Med.* 18, 97.
- WICKS, A. C. B. AND FLEMING, P. (1973) *C. Afr. J. Med.* In Press.
- WICKS, A. C. B., HOLMES, G. S. AND DAVIDSON, L. (1971) *Quar.J.med.* 40, 341.



This work is licensed under a  
Creative Commons  
Attribution – NonCommercial - NoDerivs 3.0 License.

To view a copy of the license please see:  
<http://creativecommons.org/licenses/by-nc-nd/3.0/>

This is a download from the BLDS Digital Library on OpenDocs  
<http://opendocs.ids.ac.uk/opendocs/>