

# The Central African Journal of Medicine

Volume 17

NOVEMBER, 1971

No. 11

## Rhinoscleroma

(A Report on the First Two Cases from  
Moçambique)

BY

R. AZEVEDO-BERNARDA

*Hospital Miguel Bombarda, Lourenço Marques,  
Moçambique.*

### INTRODUCTION

Rhinoscleroma, also known as lupus scrophulosus of the nostrils and, more recently, as scleroma, was described by Hebra for the first time in 1870. This author considered the first cases he encountered as peculiar forms of sarcomata, while others regarded them as luetic manifestations.

The disease appears to have been known many years before without having been isolated. Professor Bierkowsky of the University of Cracow had described it as a form of cutaneous cancer. Subsequently Geber and Mikulicz took a decisive step towards a better knowledge of the condition. Based on histopathological studies, they confirmed that it was not a neoplasm but an inflammatory condition, with peculiar characteristics. Von Frisch described the bacillus responsible for the disease which was named after him.

The designation rhinoscleroma, as it became known after Hebra's initial description, was changed to scleroma at the International Congress of othorrhynolaryngology, in order to emphasise that the disease is not confined to the nasal fossae, but spreads to other parts of the respiratory tract.

Many authors nevertheless preserve the initial designation of rhinoscleroma, since it is the more common one and, in addition, it localises the initial point of attack to the nasal fossae.

### ILLUSTRATED CASES

We know little about the clinical history of our patients. The period of time elapsing from the first symptoms to their admission to the hospital was long, but none of them know even approximately the time of onset.

(1) Patient around 25 years old, born in the Zambezia district, where he always lived. In

October, 1962, he went to the othorrhynolaryngology department of the Hospital Central Rainha Dona Amelia, in Beira, complaining of respiratory distress caused by a mass protruding from the nasal fossae, soft, reddish in colour and bleeding easily when touched. A specimen collected for histological examination showed an inflammatory granuloma, with many large cells, with clear spongy cytoplasm and cells of Mickulicz. The sections, stained with Giemsa, had many small plasma cells, neutrophils, eosinophils and Russell's bodies. There was already some tendency to fibrosis.

(2) The second patient is also an African, 36 years old, born in Quelimane, Zambezia district, a rural worker, and admitted to the Hospital Central Rainha Dona Amelia, Beira, in October, 1967, with a voluminous mass exteriorised through the nasal fossae, causing difficulty in breathing. A biopsy made on admission showed many plasma cells, Russell's bodies and a few Mikulicz cells. We observed also some tendency to fibrosis which was more accentuated at a later examination.

From the clinical point of view the lesion was not limited to the nasal fossae, but had invaded the oropharynx and larynx, making a tracheotomy necessary. Later a large part of the mass was removed surgically, and as a consequence the respiratory pathway was cleared.

### COMMENT

The disease has been described in almost every country, although it seems more frequent in certain areas.

The main focus is located in Central Europe where, according to Belinoff, it had its origin radiating from there in all directions. To the west, 498 cases were registered in Poland, 262 in Czechoslovakia and 136 in Yugoslavia.

This area forms a zone where rhinoscleroma is highly endemic. However, according to Belinoff, in his conclusions submitted to the congress in Madrid in 1932, the second zone where rhinoscleroma is less propagated, but with endemic characteristics, comprises Italy with 61 cases, Germany with 57, Rumania with 26, Hungary with 23 and Switzerland with eight. There has been



Fig. 1—Case 1 — A.  
— Swelling of the  
nasal fossae.

progressive spread of the disease towards the east. In 1881 the number of cases registered in Russia was 21 and in 1928 it was 659. In 1932, according to calculations, the Soviet Union had approximately 1,460 patients suffering from rhinoscleroma.

In Asia, according to the monograph of Kerdel-Vegas and Convit, the number of diagnosed cases was large: in China 132 cases since 1931; in Indonesia there is a focus in the Celebes Islands, the disease being described for the first time in 1918, and in 1940 there were 200 cases.

Murrel, in 1966, described 85 more cases in Indonesia, most of them also in the Celebes. Bultean recorded one case in Sydney, Australia, in a patient who had emigrated from Sicily.

In America too there are foci of some significance. In 1942 Cuning and Guerry described 102 cases in the U.S.A. In 1957 Hara recorded 47 more cases between 1942 and 1956. In Mexico in 1949, 355 cases were diagnosed. In Central America cases were found in Guatemala, S. Salvador and Costa Rica, altogether around 318.

In South America the number of recorded cases is also large. In Colombia the disease is considered frequent: Brigard collected 266 patients in a six-year interval. In Peru, Denegri described 39 cases at the second South American Congress of Otorhinolaryngology in 1945. In Chile, Del Rio recorded 30 cases in 13 years.

In Africa, which has particular interest for us, the disease is found mostly in the north near the Mediterranean basin, 40 cases having been described in Egypt and 64 in Morocco.

To the south of the Sahara the problem assumes a different form, since the number of cases described is relatively small compared to other parts of the world. It is possible that the disease may occur more frequently than it appears to do and that in the local conditions a diagnosis is often not

possible. But this fact is not of the utmost importance, since the disease is seldom found even in the best hospital.

Thus in the bibliography that we were able to compile the number of cases appeared to be too small compared to what is described above. Kafero in Uganda published a report on a case in 1951 and considers it a rarity. Vervoor described one in Ghana and also considers it exceptional. In Nigeria, as well as in the former Belgian Congo and Rwanda, a few isolated cases were described. As far as we could discover only one case has been described in South Africa. In Rhodesia, Carter reported on three cases in 1966. In Moçambique the two cases now being described are the first.

From the epidemiological point of view the disease has characteristics that make it similar to trachoma and leprosy, in which transmission is favoured by a prolonged contact in confined spaces. Substantiating this hypothesis, one finds descriptions in the literature of transmission among relatives.

Domen studied a series of 16 patients and found that some of them were relatives or had lived in close contact.

Kafero also maintains that the disease is contagious and transmissible after prolonged contact under poor conditions of hygiene. Hara in 1957 studied a series in which the disease affected a family of father, mother and five children.

Kerdel-Vegas, Convit and others, in their excellent monograph, describe a brother and sister affected simultaneously.

As regards the social environment it is a disease that affects the lower classes, more unprotected, with promiscuous habits, living under poor hygienic conditions and suffering from malnutrition. The

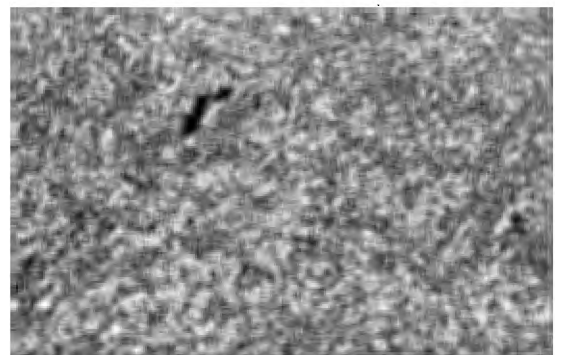


Fig. 2—Case 1 — A. — Very intense inflammatory infiltration with a great number of Mikulicz cells and plasma cells.

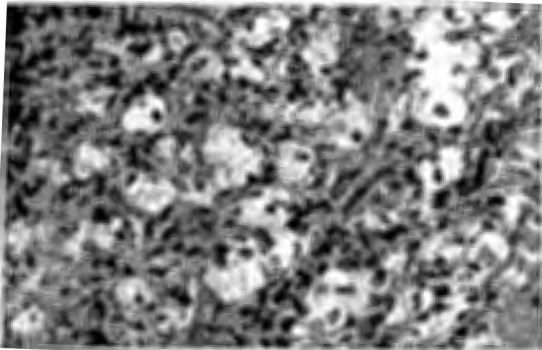


Fig. 3—Case 1 — A. — The same view with higher amplification.

influence of climate is based on the fact that the incidence in cold areas is lower. Quevedo in Guatemala suggests that altitude may have some influence. He notes that 70 per cent. of his cases are individuals living above 4,000 feet. In conclusion, we may say that rhinoscleroma is undoubtedly caused by a germ with a low degree of infectivity. According to most authors this agent would be *Bacterium rhinoscleromatis*, described by Frisch in 1882, which is a gram negative organism having some analogies with *Streptococcus pneumoniae*.

Clinically, rhinoscleroma is a disease of chronic evolution, lasting for many years, 15 or more, according to Murrel.

The anatomical structures more frequently affected are the nasal cavities, the nasopharynx, the larynx, the palate, the paranasal sinuses, the tongue, the trachea and the bronchi. It seldom affects the ear.

Although progressive, the disease runs a benign course, with preservation of the general health.



Fig. 4—Case 2 — J.W. — Large mass passing outside through the right nostril.

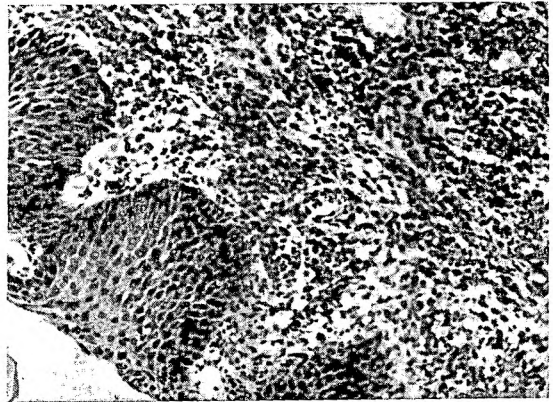


Fig. 5—Case 2 — J.W. — Epithelial hyperplasia with plasma cells infiltration and few Mikulicz cells.

The diagnosis was based on the clinical course, bacteriological and histological examination and on the complement fixation reaction. Cases of spontaneous remission are known. The evolution is characterised by different phases. In the first phase there is a mucopurulent rhinitis, during which the Frisch bacilli are already demonstrable. Later there are nodules or infiltrates, localised usually in the nasal septum, growing progressively. They can also appear in other areas of the respiratory tract and are painless.

The dominating symptoms are nasal and post-nasal obstruction, hoarseness, dysphagia, hearing defects (case described by Kafero), blocking of the lacrimae ducts and consequently epiphora. The skin is usually infiltrated with swelling of the nose (Hebra's nose).

The process becomes gradually disseminated, affecting the paranasal sinuses, palate, tonsils,

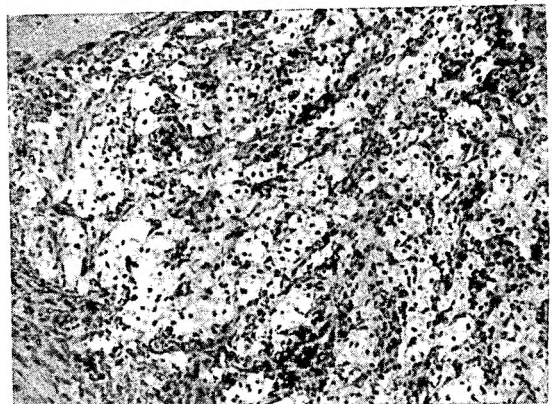


Fig. 6—Case 2 — J.W. — Infiltration with Mikulicz cells.

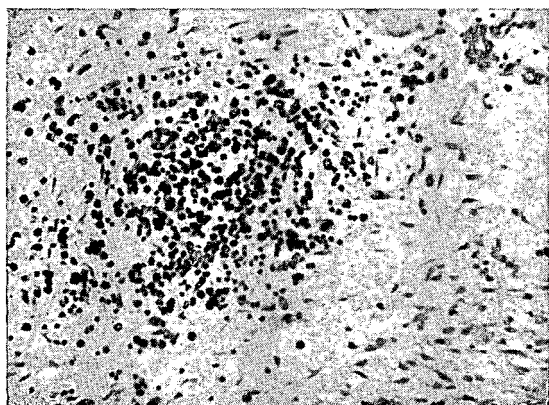


Fig. 7 — Case 2 — J.W. — Fibrosis with lymph cell and plasma cell infiltration.

pharynx, larynx and bronchi. In the end one observes the formation of scars and stenoses.

#### PATHOLOGY

Rhinoscleroma is a disease running a chronic progressive course affecting mostly the nasal fossae. The histopathological changes are initially different from the final ones, from which results the fact that the clinical aspects differ.

We can say that the disease only presents characteristic aspects in the early granulomatous phase.

The granulomatous process is extremely rich in plasma cells and contains two types of structure which give it a very peculiar appearance: the Mikulicz cells and the Russell bodies.

The Mikulicz cell is a histiocyte of round configuration, voluminous, reaching 200 microns in diameter. The cytoplasm is finely reticulated, pale, often foamy. With proper staining it is possible to detect in or out of the cells the Frisch bacilli. The Russell bodies are elliptical formations with homogeneous cytoplasm, strongly eosinophilic, refractile and enucleated. They occur inside the plasma cells and are expelled when degeneration sets in. The importance of cell infiltrates varies according to the age of the disease. The initial lesions have a very granulomatous appearance. The number of Mikulicz cells increases gradually so that at a certain stage they dominate completely the histological picture. Finally, a process of progressive fibrosis becomes established and slowly replaces the initial appearance, depriving the lesions of all characteristics of specificity.

#### CONCLUSION

Rhinoscleroma is a clinical phenomenon of little frequency in the area we work. Its clinical and histological diagnosis is not difficult, especially in the early phases. We have had the opportunity of observing two patients coming from the same region and the symptomatology of each in some aspects complements the other.

The first, detected in a more precocious stage, presented a histological picture that may be considered pathognomonic, whereas the second diagnosed at a later stage had fibrotic lesions, obscuring the initial granuloma.

#### SUMMARY

The author presents the two first cases of "rhinoscleroma" diagnosed in Moçambique, Portuguese East Africa, showing typical aspects of the sickness.

Both patients came from the same area of Zambezia. They presented with breathing difficulties, due to swelling of the external nostrils.

From the histological point of view the first case was more characteristic, since it was diagnosed at an earlier stage. It showed the granulomatous component, with several Mikulicz cells on microscopy.

The second case, diagnosed in a further stage, presented with marked fibrosis, although several Mikulicz cells were still visible.

Some comments on geographical and epidemiological distribution are made.

#### REFERENCES

- ANDERSON, W. A. D. (1966). *Pathology*, 5th Edition, Vol. 2, 767. The C. V. Mosby Company, St. Louis.
- CARTER, T. D. (1966). *C. Afr. J. Med.*, **9**, 159.
- CONVIT, J. (1961). *Arch. of Dermat.*, **84**, 55.
- KAFFERO, E. D. (1961). *E. Afr. med. J.*, **28**, 315.
- KERDEL-VEGAS, F. (1966). *Rhinoscleroma*; Editorial Científico-Médica, Barcelona.
- LEVER, W. F. (1961). *Histopathology of the Skin*. J. B. Lippincot, Philadelphia.
- MURREL, T. G. C. (1966). *Trans. Roy. Soc. trop. Med. & Hyg.*, **60**, 681.
- OOMEN, H. A. P. C. (1952). *Doc. Med. Geogr. et Trop.*, **4**, 124.
- REYNAUD, J. (1965). *Bull. Soc. Med. Afrique Noir*, **10**, 499.
- VERVOORN, J. D. (1969). *Trop. and Geogr. Med.*, **11**, 182.



This work is licensed under a  
Creative Commons  
Attribution – NonCommercial - NoDerivs 3.0 License.

To view a copy of the license please see:  
<http://creativecommons.org/licenses/by-nc-nd/3.0/>

This is a download from the BLDS Digital Library on OpenDocs  
<http://opendocs.ids.ac.uk/opendocs/>