

# The Central African Journal of Medicine

Volume 14

JANUARY, 1968

No. 1

## Xanthoma Tendinosum

### THE INFLUENCE OF ANAEMIA ON PLASMA CHOLESTEROL LEVELS

BY

PETER JACOBS,\* M.D. (Rand.), F.C.P. (S.A.)  
*Clinical Tutorial Registrar, Department of Medicine,  
University of the Witwatersrand, and the  
Johannesburg General Hospital;*

KENNETH R. BLOOM, M.B., B.CH. (Rand.)  
*House Physician, Johannesburg General Hospital, pre-  
sently Medical Registrar, Cautisthoracic Unit, General  
Hospital, Johannesburg.*

AND

MOSES M. SUZMAN, M.D., F.R.C.P.  
*Physician, Johannesburg General Hospital, presently in  
the Department of Medicine, University of Washington  
School of Medicine, Seattle, Washington, U.S.A.*

The formation of xanthomata in tendons occurs typically as part of a familial disorder associated with an elevation of the total plasma cholesterol. In those cases where the tendinous deposits are small in size and few in number, the cholesterol level is usually only moderately raised, extensive deposits being more commonly associated with much higher levels. It is therefore of interest to have encountered a patient with a severe degree of xanthoma tendinosum whose plasma cholesterol was in the normal range.

#### CASE REPORT

The patient, a 39-year-old white housewife, was admitted to the medical wards of the Johannesburg General Hospital because of haemorrhage from the gastrointestinal tract; in the six hours preceding admission she had passed two large melaena stools and immediately on admission vomited about one pint of fresh blood. For several days before this the patient had consumed large quantities of acetosalicylic acid to relieve her dysmenorrhoea, a practice which she had followed regularly since her menarche at 16 years of age.

For 10 years the patient had suffered intermittent attacks of painful swelling of the small joints of her hands and feet, at times the latter being severe enough to prevent her from walking. During the same period of time firm nodules in the tendons on the dorsum of her

hands and at the back of her heels had appeared; these had been slowly increasing in size. Her mother, who died of an acute myocardial infarction at the age of 68, and an elder sister had similar nodules on their hands and ankles. Both women, together with her younger brother and her eldest son, experienced arthritic pains.

On examination the patient was pale and a well-marked bilateral corneal arcus was noted. The blood pressure was 125/60 mm. Hg. A grade 2/6 aortic ejection systolic murmur was audible at the base of the heart. The achilles tendons were markedly thickened (Fig. 1) and firm non-tender nodules were present in the extensor tendons of the index and middle fingers of both hands (Fig. 2). Varicose veins were prominent in the left leg and a chronic stasis ulcer was present just above the left medial malleolus. Rectal examination showed only the presence of melaena stool.

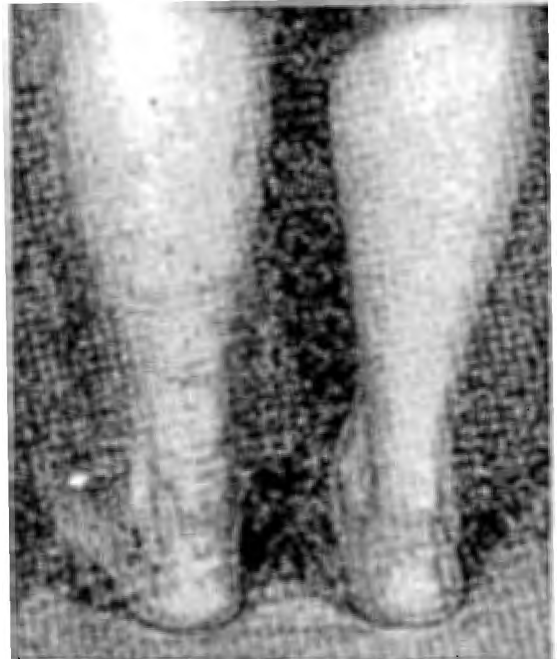

Fig. 1—Photograph illustrating grossly thickened Achilles tendons.

\* Eli Lilly Medical Research Fellow.

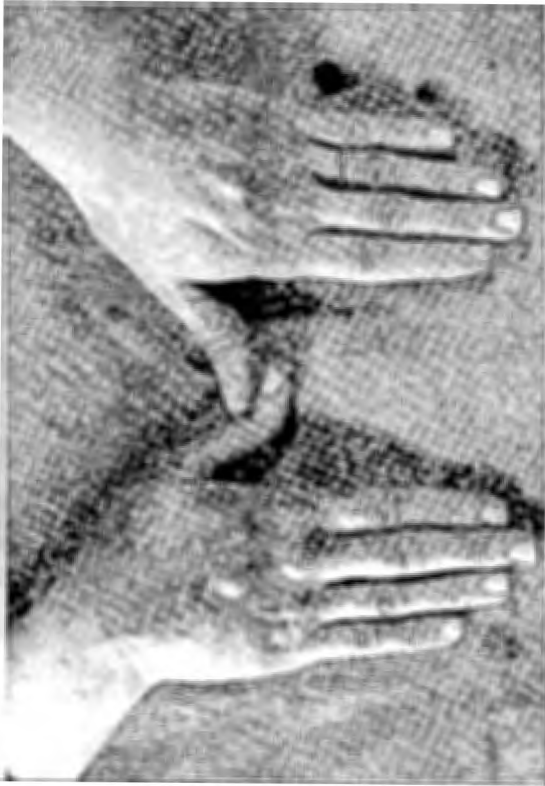

Fig. 2—Photograph to demonstrate extensive involvement of extensor tendons with xanthomata.

Investigations on admission showed the following: Haemoglobin, 9.5 gm. per cent.; total leucocyte count, 7,100 per cu.mm., neutrophiles, 68 per cent.; monocytes, 5 per cent.; lymphocytes, 24 per cent., and eosinophiles 3 per cent.; platelets, 460,000 per cu.mm.; prothrombin index, 98 per cent.; bleeding and clotting times were both normal. Serum iron was 20 micrograms per cent. and unsaturated iron binding capacity 380 micrograms per cent. Blood sugar was 92 mg. per cent., fasting total lipids were 630 mg. per cent., total cholesterol 236 mg. per cent., free cholesterol 62 mg. per cent., and a cholesterol:phospholipid ratio of 1.02. Fatty acids were 322 mg. per cent., triglycerides 35 mg. per cent., beta-lipoproteins 60 per cent. and beta-cholesterol 79 per cent. The serum protein bound iodine was 7 micrograms per cent.

Electrocardiographic abnormalities were confined to a 2 mm. plane depression of the ST segments and inverted T waves in V 3, V 4, V 5 and V 6.

Detailed radiological investigations of the gastrointestinal tract failed to reveal any abnormality to account for the bleeding. In view of

the clear history of salicylate ingestion and the negative barium studies, it appeared most likely that the haemorrhage was due to acute gastric erosion. The patient responded well to treatment with anticholinergics and blood transfusion; a course of oral iron therapy was started before she was discharged from hospital.

\*Biopsies were carried out on the tendon nodules, and sections from these showed typical clefts (Fig. 3) which remained after dissolution of cholesterol crystals during histological preparation. In addition, numerous foam or xanthoma cells were seen, together with polymorphonuclear leucocytes, lymphocytes and histiocytes (Fig. 4). The "touton" giant cells characteristic of young, active lesions were not seen; the fibrosis present indicated that these lesions were in a stage of involution.

\* Reported by Dr. H. E. van der Merwe and Dr. N. S. F. Proctor, Department of Histopathology at the South African Institute for Medical Research.

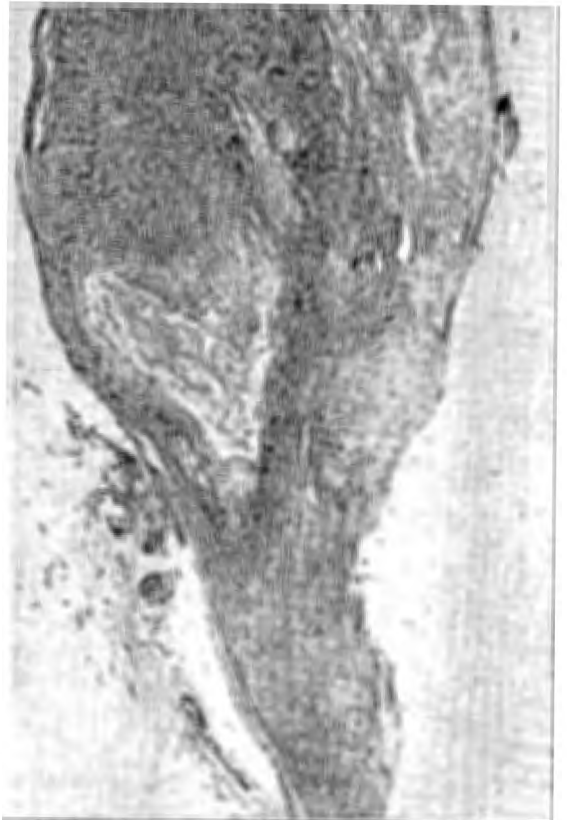

Fig. 3—Low power view of xanthomatous deposit in tendon sheath. Note the clefts normally occupied by cholesterol crystals.

DISCUSSION

The interest of this case lies in the association of a normal lipogram with marked corneal arcus, an extreme degree of tendinous xanthoma formation and a very strong family history of the latter condition.

In view of the widespread xanthomatous deposits a marked elevation of the blood cholesterol could reasonably have been expected. However, as this was not a feature on admission, it was considered possible that the level may have fallen consequent upon the development of iron-deficiency anaemia due to chronic blood loss from the gastrointestinal tract. Support for this hypothesis was obtained by documenting the rise in plasma cholesterol, to pathologically high levels, as the haemoglobin had returned to normal (Fig. 5). These observations are in accord with earlier work (MacAdam and Shiskin, 1923), which indicated that disturbances in cholesterol metabolism frequently accompany anaemia. This association was most apparent in pernicious anaemia (Gibson and Howard, 1923; Muller,

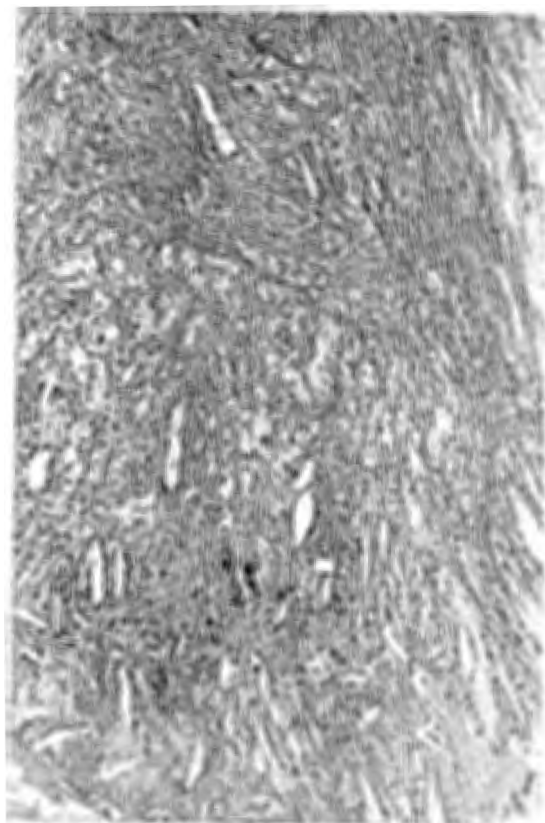


Fig. 4—High power view of xanthomatous lesion showing numerous xanthoma cells and "cholesterol clefts."

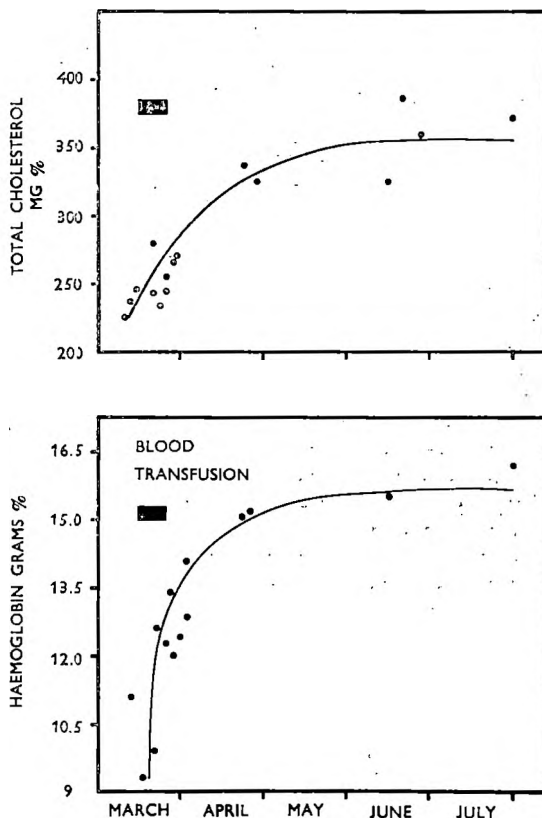


Fig. 5—Graphs illustrating the close relationship between elevation of plasma cholesterol level and correction of anaemia.

1930a), where the cholesterol, and frequently plasma lecithin-phosphorus, were decreased during relapse, but rose as remission was inaugurated; this rise in cholesterol often developed before significant alterations had occurred in the concentration of erythrocytes or haemoglobin and was proportional to the rate of remission.

Muller and Heath (1933) stressed that cholesterol is also low in chronic blood loss anaemia and rises gradually to normal limits when treatment with iron is instituted. It is of some interest that isolated acute blood loss anaemia affects lipids and cholesterol differently to chronic blood loss. Thus, in both experimental animals (Louhija, 1965) and in man (Campbell, 1925), there is a rise in lipids and cholesterol immediately following haemorrhage. Understandably, in those patients where acute blood loss was superimposed upon chronic iron deficiency, an intermediate pattern emerged upon study.

The mechanism by which this lowering of plasma cholesterol is brought about remains

obscure, but it has been suggested (Muller, 1930b) that the fall may reflect changes in the functional activity of the reticuloendothelial system. In this regard it is of some interest that cholesterol tends to be reduced in haemolytic states where increased blood destruction and bile formation point to accelerated activity in this system of cells. Similarly, in pernicious anaemia, the accelerated blood destruction and bilirubinaemia decrease with the onset of the clinical and haematological remission, at a time when the plasma cholesterol starts to increase. Furthermore, the anaemia caused by chronic blood loss is associated with excess haemolysis (Huser, Rieber and Berman, 1967) and here, likewise, a similar mechanism may be operative in depressing plasma cholesterol values. Additional support for the relationship of cholesterol metabolism to cell proliferation in the bone marrow can be inferred from the low values found in chronic myelogenous leukaemia (Muller, 1930b) and in acute infectious diseases like pneumonia (Kipp, 1920).

These observations, even though not fully understood, may have significance for the pathogenesis and management of atherosclerosis and its complications, since the latter are widely held to be among the chief consequences of familial hypercholesterolaemia and other hyperlipidaemias. Thus, assuming that the high levels of blood fats do actually promote these pathological changes, it may be speculated that in chronic blood loss anaemia such complications would be less likely to ensue. In other words, individuals who, in ordinary circumstances, would have high blood fats and cholesterol by reason of dietary or genetic predisposition, may have normal lipids while they remain anaemic; it follows that such a group might consequently enjoy a certain amount of protection from the results of their metabolic derangement.

Furthermore, evidence is now accumulating in support of the association between myocardial infarction and elevation in the blood haematocrit (McDonough, Hames, Garrison, Stulb, Lichtman and Hefelfinger, 1965; Burch and De Pasquale, 1962) and, indeed, phlebotomy has been used as a means of treatment in patients with erythrocytosis and ischaemic heart disease (Burch and De Pasquale, 1963). In considering the available evidence it seems reasonable to suggest that repeated venesections may have a place in management of selected patients with atherosclerosis: short term effects being related to reduction in haematocrit, while induction and long term maintenance of iron deficiency may favourably influence the level of plasma cholesterol.

That this inverse correlation between hypercholesterolaemia and anaemia is far from absolute is exemplified by those patients with very high lipid and cholesterol levels while severely anaemic from such conditions as the nephrotic syndrome. In these cases it may be that the function of the reticuloendothelial system is impaired as a result of concurrent infection. Nevertheless, it remains uncertain whether this association between anaemia and the plasma cholesterol level applies only to cases having significant lipid abnormalities in the first place, or whether it has, in addition, any relevance for normocholesterolaemic subjects.

#### SUMMARY

A young female with well-established xanthoma tendinosum presented with anaemia due to salicylate-induced gastrointestinal tract haemorrhage. Initially, the lipogram was normal, but pathological elevation of cholesterol followed correction of her anaemia. This phenomenon appears to have been well studied some 30 years ago, but, more recently, seems to have been less frequently recognised. The implication of this association in respect of the pathogenesis and management of patients with atherosclerosis is briefly discussed.

#### REFERENCES

1. BURCH, G. E. & DE PASQUALE, N. P. (1962). *Am. J. Med.*, **32**, 161 (Editorial).
2. BURCH, G. E. & DE PASQUALE, N. P. (1963). *Arch. Int. Med.*, **III**, 687.
3. CAMPBELL, J. M. H. (1925). *Quart. J. Med.*, **18**, 393.
4. GIBSON, R. B. & HOWARD, C. P. (1923). *Arch. Int. Med.*, **32**, 1.
5. HUSER, H. J., RIEBER, E. E. & BERMAN, A. R. (1967). *J. Lab. Clin. Med.*, **69**, 405.
6. KIPP, H. A. (1920). *J. Biol. Chem.*, **44**, 215.
7. LOUHLJA, A. (1965). *Ann. Med. Exp. Fenn.*, **43**, (Supp. 2), 1.
8. MACADAM, W. & SHISKIN, C. (1923). *Quart. J. Med.*, **16**, 193.
9. McDONOUGH, J. R., HAMES, C. G., GARRISON, G. E., STULB, S. C., LICHTMAN, M. A. & HEFELFINGER, D. C. (1965). *J. Chron. Dis.*, **18**, 243.
10. MULLER, G. L. (1930a). *Am. J. Med. Sc.*, **179**, 316.
11. MULLER, G. L. (1930b). *Med.*, **9**, 119.
12. MULLER, G. L. & HEATH, C. W. (1933). *Arch. Int. Med.*, **52**, 288.

#### Acknowledgments

The photography was done by the photographic unit of the Department of Medicine and photomicrographs by the South African Institute for Medical Research. Dr. H. van Wyk, Medical Superintendent, Johannesburg General Hospital, granted permission to publish.



This work is licensed under a  
Creative Commons  
Attribution – NonCommercial - NoDerivs 3.0 License.

To view a copy of the license please see:  
<http://creativecommons.org/licenses/by-nc-nd/3.0/>

This is a download from the BLDS Digital Library on OpenDocs  
<http://opendocs.ids.ac.uk/opendocs/>