



# THE CENTRAL AFRICAN JOURNAL OF MEDICINE



Vol. 55, Nos. 5/8

CONTENTS

May/August 2009

## ORIGINAL ARTICLES

Which factors actually influence the development and progression of overt nephropathy in Nigerian Diabetics?.....

A Ibrahim, FA Arogundade, AA Sanusi, R Ikem, AO Akintomide, AA Akinsola.....28

The role of echocardiography in the management of patients with congestive heart failure.....

EE Maro, R Kaushik.....35

Osteosarcoma of the jaws: a 23 year retrospective review .....

MM Chidzonga, L Mahomva.....40

## CASE REPORTS

Salivary gland tumours of the lip: report of two cases and literature review.

ME Asuquo, OO Otei, R Ekpo, I Abang, U Adams, EE Bassey, G Ebughe.....43

## NOTES AND NEWS

Instructions to Authors.....

*Central African Journal of Medicine*.....46

---

## **EDITORIAL BOARD**

### **EDITOR IN CHIEF**

Professor IT Gangaidzo

### **ASSOCIATE EDITOR**

Professor KJ Nathoo

Dr S Munjanja

### **EDITORIAL BOARD MEMBERS**

<i>Professor MM Chidzonga</i>	<i>Zimbabwe</i>
<i>Professor L Gwanzura</i>	<i>Zimbabwe</i>
<i>Professor R Kambarami</i>	<i>Zimbabwe</i>
<i>Dr CE Ndlovu</i>	<i>Zimbabwe</i>
<i>Professor P Jacobs</i>	<i>South Africa</i>
<i>Mr L Nystrom</i>	<i>Sweden</i>

### **PAST EDITORS**

*Professor M Gelfand (1953-1985)*

*Professor HM Chinyanga (1985-1990)*

*Professor JA Matenga (1991-1999)*

*Professor GI Muguti (2000-2004)*

### **ADMINISTRATIVE AND OFFICE STAFF**

*Director of Publications: Mr Munani S Mutetwa*

*Administrative Manager: Mr Christopher B Mashavira*

*Technical Editor: Mrs Ling M Cooper*

*Statistics Advisor: Prof. S Rusakaniko*

*Secretary/Typesetter: Ms Crathilwe Nyathi*

All manuscripts will be prepared in line with the International Committee of Medical Journal Editors' uniform requirements for manuscripts submitted to Biomedical Journals.1993. Manuscripts submitted for publication are accepted on the understanding that they are contributed exclusively to the *Central African Journal of Medicine*. A statement to that effect should be included in the letter accompanying the manuscripts. Communications concerning editorial matters, advertising, subscriptions, change of address, etc. should be addressed to the Administrative Manager, P. O. Box A195, Avondale, Harare, Zimbabwe.

Owned and Published by the Central African Journal of Medicine in Conjunction with the College of Health Sciences, University of Zimbabwe.



University Of Zimbabwe

---

---

## CASE REPORTS

---

### Salivary gland tumour of the lip: report of two cases and literature review

\*ME ASUQUO, \*OO OTEI, \*R EKPO, \*I ABANG, \*U ADAMS, \*\*EE BASSEY, \*\*G EBUGHE

#### Abstract

**Background:** Salivary gland tumours (SGT'S) are uncommon. The minor glands are dispersed throughout the upper aerodigestive submucosa including the lip.

**Objective:** To present two case reports of salivary gland tumour of the upper lip and highlight its diagnostic and therapeutic challenges.

**Case reports:** A 50 year old female farmer presented with a two year history of swelling of the upper lip and the histology revealed a pleomorphic adenoma of the minor salivary gland. She was offered a wide excision which resulted in a huge upper lip defect managed by a two staged lip switch ABBE flap. The second patient, a 40 year old female teacher presented with a 10year history of a left sided upper lip swelling. Histology revealed pleomorphic adenoma. She was offered an excision with no evidence of recurrence after 26 months of follow up.

**Conclusion:** Salivary gland tumours should be considered as a differential diagnosis of tumours of the lip. Early presentation is advocated as late presentation with advanced tumour presents diagnostic and therapeutic challenges.

#### Introduction

Salivary gland tumours (SGT'S) are uncommon; they represent 2.4% of head and neck neoplasm and include tumours affecting both major and minor salivary glands.<sup>1,2</sup> The glands are divided into major and minor salivary gland categories. The major salivary glands are the parotid, submandibular and sublingual glands. The minor glands are dispersed throughout the upper aerodigestive submucosa (palate, tongue, lip, pharynx, nasopharynx, larynx, parapharyngeal space) and

*Cent Afr J Med 2009;55(5/8) 43-6*  
account for 22% of tumours.<sup>2</sup> The lip has three major anatomical parts; skin, muscle and mucous membrane with numerous salivary glands in the submucosa. Pleomorphic adenomas (benign mixed tumours) are the most common benign SGT and comprise 85% of all salivary gland neoplasms.<sup>2</sup> However, the incidence of SGT'S is claimed to be influenced by geographic and racial factors.<sup>3</sup> African reports suggest a pattern that significantly differs from that of western countries.<sup>4</sup> The ubiquitous deposits of the minor salivary glands complicate the diagnosis and management.<sup>2</sup> We

Departments of \*Surgery and \*\*Pathology  
University of Calabar Teaching Hospital  
Calabar, Nigeria

Correspondence to:

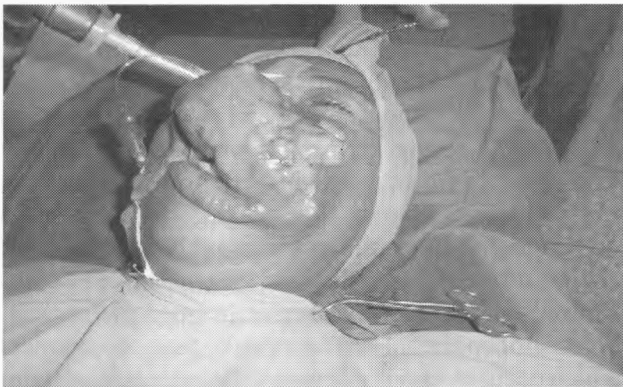
Dr ME Asuquo  
P O Box 1891 (GPO)  
Calabar, Nigeria.  
Email: [mauefas@yahoo.com](mailto:mauefas@yahoo.com)

present two cases, one of which was an advanced tumour of the minor salivary gland of the upper lip, to highlight the diagnostic and therapeutic challenges.

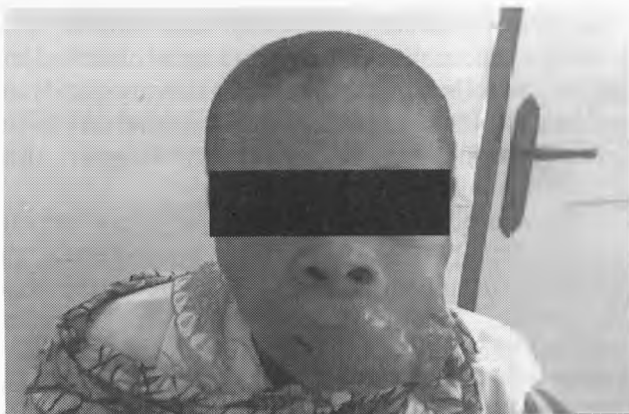**Case Report 1:** EES, 130615, a 50 year old female trader presented with a two year history of swelling of the upper lip. This lesion started as a small painless swelling that involved the inner part of the upper lip. It progressively increased in size, resulted in difficulty in moving the upper lip and affected her phonation. There was no history of trauma, itching, smoking or exposure to radiation. She applied topical local herbal medications, rinsed her mouth with local gin and consulted some medical facilities, to no avail. Presentation to the University of Calabar Teaching Hospital was prompted when the mass began to bleed on contact.

Examination revealed a middle age female, afebrile, not pale. There was a huge, irregular, firm, fungating multilobulated mass involving the upper lip measuring 16cm across the widest diameter, (Figure 1a). It was attached to the skin and mucosa with multiple ulcerations. The lesion was not tender, neither pulsatile nor warmer than the surrounding. There was no regional lymphadenopathy. Chest and abdomen were normal.

*Figure 1a: Salivary gland tumour; oral view.*



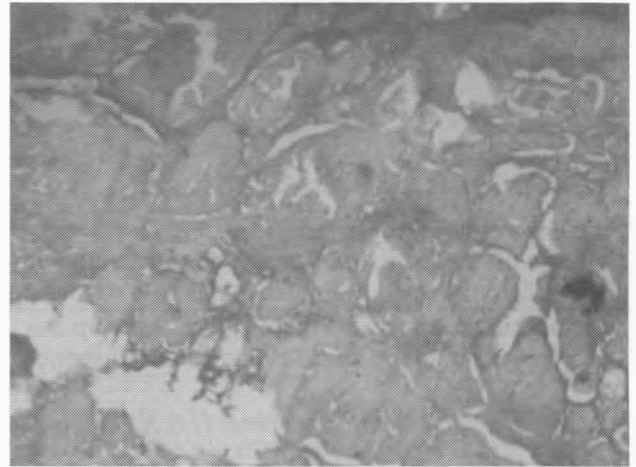
*Figure 1a: Salivary gland tumour; facial view.*



Work up revealed a PCV of 30%, WBC  $3.0 \times 10^9/l$ . Urinalysis and chest X-ray were normal. Biopsy

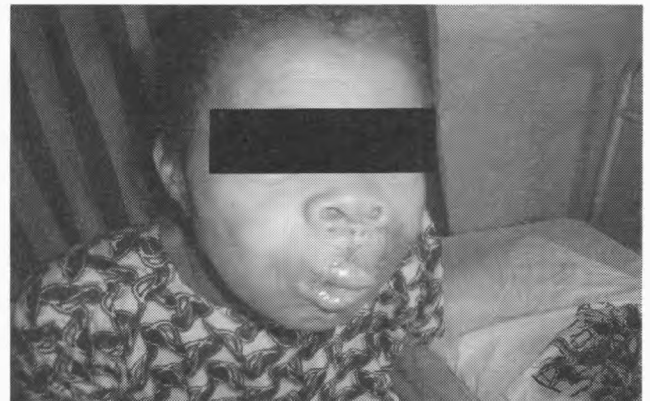showed a tumour composed of myoepithelial like cells in a myxoid background with chondroid looking cells. The tissue was lined by non keratinised epithelium. There was no atypia- pleomorphic adenoma, (Figure 1b).

*Figure 1b: Pleomorphic adenoma; H & E x 40.*



She had an excision and a two staged upper lip reconstruction with lip switch ABBE flap, (Figure 1c). Follow up has been for three months.

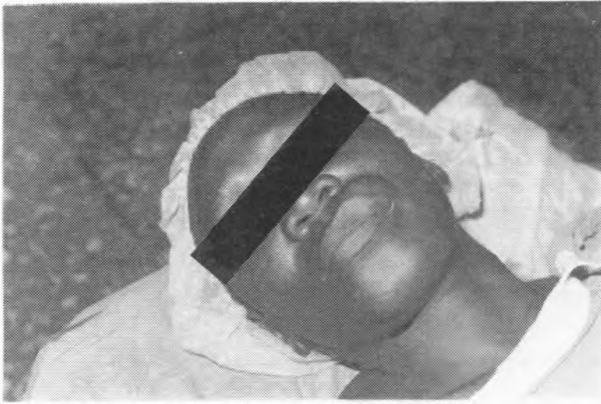*Figure 1c: Post excision and upper lip reconstruction.*



**Case Report 2:** FOE 066932, a 40 year old female teacher presented with a 10 year history of a slow growing swelling that involved the upper lip. This was first noticed while brushing her teeth. There was no previous history of trauma or itching, she neither smoked nor was exposed to radiation and used traditional herbal medication to no avail.

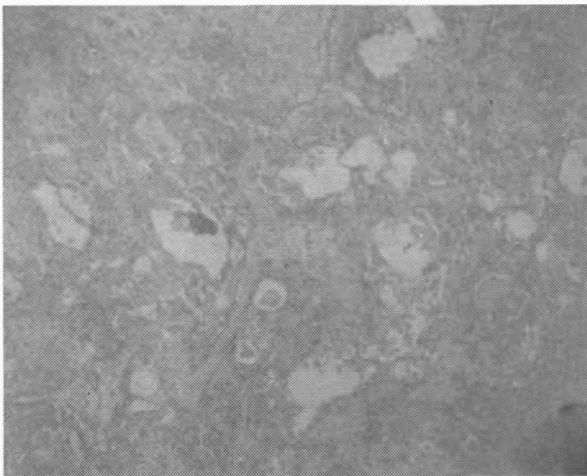
Examination revealed a middle aged female, afebrile and not pale. There was a left sided upper lip mass, firm, non tender mobile mass that measured 4x3cm, (Figure 1Ia). It was not attached to skin or mucosa and there was no regional lymphadenopathy. Chest and abdomen was normal. Work up revealed a PCV of 30%, WBC  $3.6 \times 10^9/l$  and a normal urinalysis.

Figure IIa: Salivary gland tumour.



She was offered excision through an oral route with local infiltration using lignocaine. Histology revealed pleomorphic adenoma, (Figure IIb). Follow up has been for 26 months with no evidence of recurrence.

Figure IIb: Pleomorphic adenoma; H & Ex 40.



## Discussion

The rarity of SGT'S in addition to few reported cases on minor salivary tumour lessens its clinical awareness.<sup>1</sup> Generally the major salivary gland has the highest incidence of tumours with 85% being pleomorphic adenoma (parotid, 70%, submandibular 8%, minor, 22%).<sup>2</sup> However, Edda in Uganda<sup>3</sup> reported a low proportion of tumour from parotid and high proportion of tumours of the submandibular and minor salivary glands (parotid, 30%, submandibular, 33.2% and 32.8% from minor salivary glands). In Ethiopia minor SGT constituted 31.9% of SGT'S.<sup>4</sup> Odukoya in Lagos, Nigeria reported a higher percentage of minor SGT'S, 68.9% and major, 31.1%.<sup>5</sup> African series have suggested a pattern of presentation that significantly differs from that of western countries.<sup>4</sup> The presentation of these patients is aimed at increasing the awareness of this tumour that may present in grotesque picture with therapeutic challenges as depicted in Case 1.

The highest incidence has been found in patients in the fifth to seventh decade with females commonly affected.<sup>1,3</sup> Our patients were females in the fourth and fifth decades. Chalin<sup>2</sup> reported the peak age of third to fourth decade and Odukoya<sup>5</sup> in Nigeria reported a mean age of 31 years (11 to 75 years) with a slight male preponderance (8:7) on pleomorphic adenoma of minor and major salivary glands.

The ubiquitous depositions of minor salivary glands complicate diagnosis and management. The classic presentation of benign SGT'S is a painless slow growing mass but because of the multiple and varied site of the minor salivary gland the presentation may be less specific. Pleomorphic adenomas (benign mixed tumours) are the most common tumour of the salivary gland. When found in the minor salivary glands the hard palate is the site most frequently involved followed by the upper lip, the site involved in our patients. Tumours of the lip could arise from the skin, muscle and the mucosa. Clinical diagnosis may be possible with early presentation when the lesion is confined to the tissue of origin. Late presentation with grotesque picture as was in Case 1 made clinical diagnosis difficult as the skin and muscles were involved and diagnosis was made on histology.

Histologic diagnosis is required prior to definitive surgical treatment. Fine needle aspiration cytology (FNAC) may aid in the diagnosis with the aid of an experienced cytologist but histology is required for final pathologic diagnosis.<sup>2</sup> Magnetic resonance imaging, (MRI) is the most sensitive for establishing the borders of soft tissue tumour extension. Computerised tomography (CT) and MRI may not differentiate benign from malignant disease reliably.<sup>2</sup> The histologic diagnosis of our patient was pleomorphic adenoma, (Figure Ib, IIb). It comprised myoepithelial-like cells in a myxoid background with chondroid looking cells and was lined by non keratinised epithelium. They are termed pleomorphic because of epithelial and connective tissue components which occur in varying degrees. Pleomorphic adenoma originates from the intercalated duct cells and myoepithelial cells. Oncocytic tumours originate from striated ducts cells, acini cell tumour from acinar cells, mucoepidermoid and squamous cell tumour from excretory duct cells.<sup>2</sup> Odukoya in Lagos<sup>5</sup> observed less chondroid cells in minor than major salivary glands and remarked that tumours with epithelial tissue predominance were generally bigger than mesenchymal tissue predominance.

Pleomorphic adenomas from the minor salivary glands usually lack a capsule, consequently the avoidance of spillage at surgery is required to minimise recurrence. Benign neoplasm requires complete surgical excision and MOH'S micrographic surgery (MMS) is the gold standard. Our patient (Case 1) was offered wide excision which resulted in a huge upper lip defect managed by a two staged lip switch ABBE flap. Case 2 had excision and primary closure under local anaesthesia because the tumour was localised and

posed no therapeutic challenge.

Tumours of the minor salivary glands should be considered in the diagnosis of patients with lip lesions. Early presentation would improve outcome and follow up is required as the risk of tumour recurrence is high.

### References

1. Pires FR, Pringle GA, de Almeida OP, Chan SY. Intra-oral minor salivary gland tumours: a clinicopathological study of 546 cases. *Oral Oncol* 2007; 43(5):463-70.
2. Chahin F, Kaufman MR, Abbarah T, Chahin C. Salivary gland tumours. *e-Med J* 2005;Nov 18<sup>th</sup>:1-14.
3. Edda AM, Vuhahula. Salivary gland tumour in Uganda: clinicopathological study. *Afr Health Sciences* 2004;4(1):15-23.
4. Ergicho B, Ergicho B. Pattern of salivary gland tumours in Ethiopia and non-western countries. *Ethiop Med J* 2003;41(3):235-44.
5. Odukoya O. Pleomorphic adenoma of the salivary glands in Lagos, Nigeria: clinicopathological analysis of 45 cases. *Cent Afr J Med* 1990;36(10):251-6.

---

## NOTES AND NEWS

---

### Instructions to Authors

*The Central African Journal of Medicine* is a refereed journal which seeks to promote the practice and science of medicine in Zimbabwe, in other parts of Africa, and the rest of the world in general. Original articles are accepted for publication on the understanding that they are contributed **exclusively** to this journal and become its property. Articles are subject to such alterations as the Editor in his absolute discretion may deem necessary. No major alterations will be made without consent of the author.

#### Summary of Requirements

Submit three copies of the manuscript on paper and one on diskette, written in English. Type the manuscript **double spaced**, including title page, structured abstract (summary), text, acknowledgements, references, tables (each table complete with title and footnotes, on a separate page), and legends for illustrations. Illustrations must be good quality, unmounted glossy prints, usually 17 x 173 mm (5 x 7 in.), but no larger than 203 x 254 mm (8 x 10 in.).

When submitting diskettes authors should:

1. Be sure to include three print outs of the manuscript version on the diskette.
2. Make sure the diskette is clearly labelled with the title and name(s) of author(s).
3. The diskette must be IBM compatible on Ms Word format up to version 2000.

The submitted manuscript should be accompanied by a covering letter stating that it is **solely submitted** to this journal and authors should keep copies of everything submitted.

#### Preparation of Manuscript

Type or print out the manuscript on white bond paper, 216 x 297 mm (8,5 x 11 in.), or ISO A4 (212 X 297 mm), with margins of at least 25 mm (1 in.). Type or print on only one side of the paper. Use **double spacing** throughout, including title page, abstract (summary), text, acknowledgements, references, individual tables, and legends. Number pages consecutively, beginning with the title page. Put the page number in the upper or

lower right hand corner of each page. Tables and figures must be referred to by Roman numerals e.g. Table I. Drugs should be given their approved not proprietary names.

#### Title page.

The title page should carry:

- a) the title of the article which should be concise but informative;
- b) initials and last name of each author, with highest academic degree(s) and institutional affiliation;
- c) name of department(s) and institution(s) to which the work should be attributed;
- d) disclaimers, if any;
- e) full name and address of author responsible for correspondence about the manuscript;
- f) full name and address of author to whom requests for reprints should be addressed or statement that reprints will not be available from the author.

#### Abstract.

The second page should carry a structured abstract. An abstract should be of no more than 250 words under the following headings:

Objective, Design, Setting, Subjects, Interventions (if any), Main outcome measure(s), Results, Conclusion.

**Objective:** State the main objective(s) or question(s) addressed in the report.

**Design:** Describe the basic design of the study using the following terms that may apply to the study e.g

- a) Intervention studies: randomized or non-randomized control trial; double blind; placebo control; crossover trial before-after trial.



This work is licensed under a  
Creative Commons  
Attribution – NonCommercial - NoDerivs 3.0 License.

To view a copy of the license please see:  
<http://creativecommons.org/licenses/by-nc-nd/3.0/>

This is a download from the BLDS Digital Library on OpenDocs  
<http://opendocs.ids.ac.uk/opendocs/>