



# THE CENTRAL AFRICAN JOURNAL OF MEDICINE

Vol. 57, Nos. 5/8

CONTENTS

May/August 2011

## ORIGINAL ARTICLES

- Snakebite admissions in Zimbabwe: Pattern, clinical presentation and management..... D Tagwireyi, DE Ball, CFB Nhachi.....17
- The effects of hospitalization on the sleep patterns of patients aged 20- 30 years old admitted at a central Hospital in Harare, Zimbabwe..... HV Gundani, K Matongo.....23
- Factors Associated with Occupational Injuries at a beverage manufacturing company in Harare, Zimbabwe; 2008..... G Gonese, M Tshimanga, J Chirenda, A Chadambuka, NT Gombe, G Shambiras.....26

## CASE REPORT

- Cecal volvulus in pregnancy: a case report ..... OB Chihaka.....32

## NOTES AND NEWS

- Instructions to Authors..... *Central African Journal of Medicine*.....36

## CECAL VOLVULUS IN PREGNANCY: A CASE REPORT

OB CHIHAKA

### Introduction

Volvulus of the cecum is an axial twist or folding of the bowel on its mesentery resulting in acute intestinal obstruction.<sup>1</sup> The incidence of cecal volvulus during pregnancy has been reported in some centres to be between 1:2500 to 1:3500 deliveries.<sup>2</sup> Colonic volvulus is the second most common cause of intestinal obstruction in pregnancy after adhesions and tends to occur prior to onset of labour.<sup>3</sup>

### Case Report

A 29 year old para 5, gravida 7 was admitted by the obstetricians at 32 weeks gestation with a one day history of sudden onset of peri-umbilical pain associated with absolute constipation and a single episode of bilious vomiting. She also reported that she had not felt any fetal movements from the onset of symptoms.

On examination she was an ill looking patient who was apyrexial. She was pink and was dehydrated. Her blood pressure was 110/75mmHg and pulse was 80 beats per minute. She had a tachypnoea of 32 breaths per minute. The abdomen was globally distended with generalised tenderness. The uterus was bulky in keeping with the pregnancy. However there was no fetal heart. A clinical diagnosis of intra-uterine death secondary to abruptio placenta was made and labour was induced. The labour progressed well and she delivered an early macerated stillbirth 16 hours after induction. The placenta was complete with no retro-placental hematoma and thus this was not an abruptio. Post delivery the patient's condition was noted to continue deteriorating. The abdomen remained distended mainly in the epigastric region and the abdomen was silent. The obstetricians then send a

Cecal volvulus tends to present with intermittent abdominal cramps, nausea and vomiting and constipation. Unfortunately these symptoms are usually attributed to the normal discomforts of pregnancy by both the patient and physician leading to delayed presentation and delayed diagnosis.

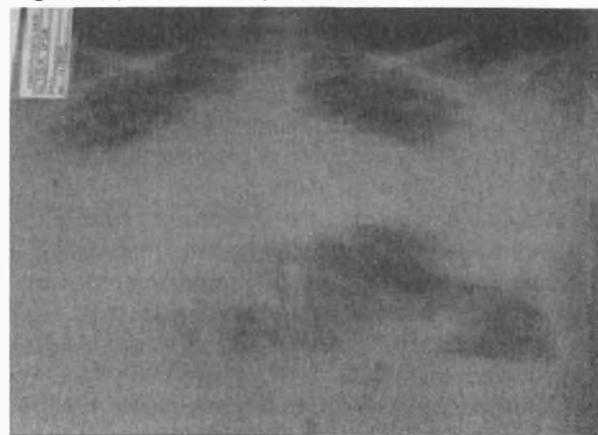
In this paper we present a case of delayed diagnosis of cecal volvulus highlighting the reasons for and consequences of delayed diagnosis.

*Cent Afr J Med 2011;57(5/8) 32-35*

consult to us.

When we saw the patient she had a grossly distended abdomen with an obvious epigastric prominence. It was moving minimally with respiration. There was some mild generalised abdominal tenderness and bowel sounds were absent. The rectum was empty. We ordered a chest X-ray and abdominal X-ray which showed marked splinting of the diaphragm and a bean shaped loop of large bowel and distended loop of small bowel in the epigastrium (Figure I).

Figure I(a): Chest x-ray.



Correspondence to:

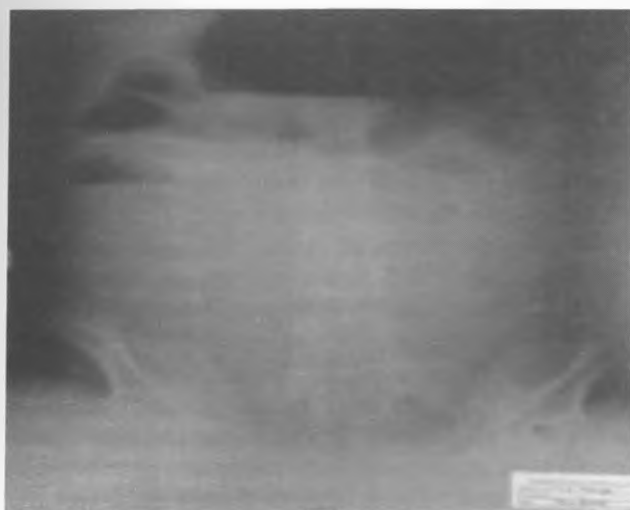
Department of Surgery  
University of Zimbabwe, College of Health Sciences  
P O Box A178  
Avondale, Harare  
Zimbabwe

Dr OB Chihaka  
Department of Surgery  
University of Zimbabwe, College of Health Sciences  
P O Box A178  
Avondale, Harare  
Zimbabwe

Figure 1(B): *Abd supine x-ray.*

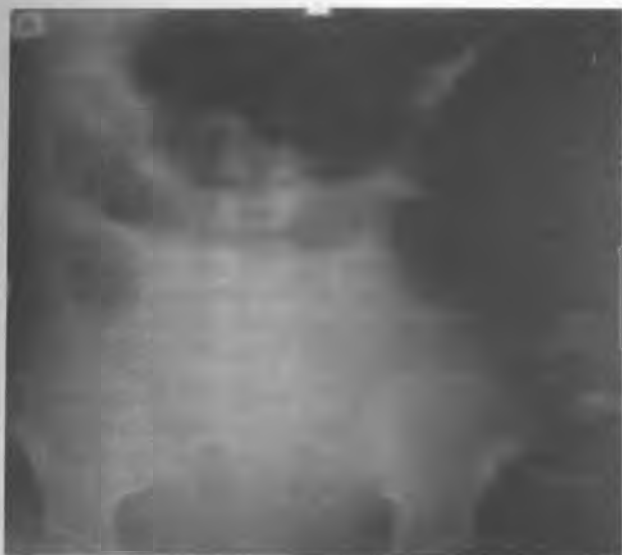

Figure 1(c): *Abd erect x-ray.*



An impression of intestinal obstruction was made. A nasogastric tube was inserted and drained about 500ml of bilious material. She was rehydrated with Normal Saline and put on oxygen per face mask.

She had a white cell count of 5.8, Haemoglobin of 15g/dl. Hematocrit of 51%, MCV 78.3 and platelet count was 237 000. Her urea and electrolytes were normal. During resuscitation her respiratory function was worsening and oxygen saturation went down to 80% on oxygen per face mask. We made arrangements for an urgent laparotomy.

At laparotomy a gangrenous cecal volvulus was noted lying in the left upper quadrant and all the small bowel was located in the right lower quadrant. The duodenum was not crossing the midline. She had intestinal malrotation. We drained about one litre of haemorrhagic ascites.

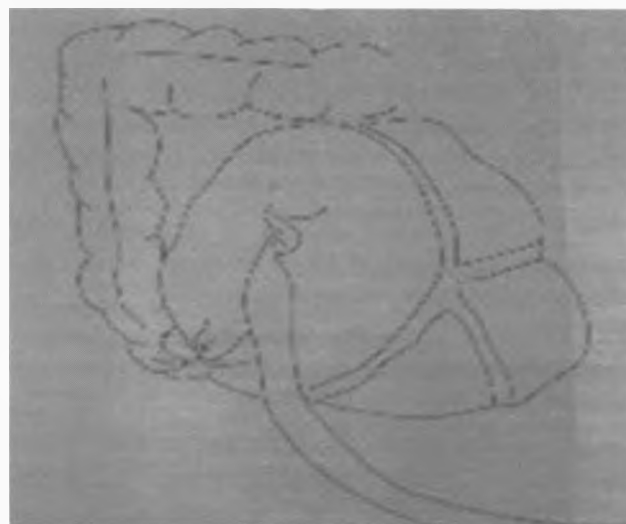
On decompression of the abdomen the blood pressure dropped to 70/40mmHg (Mean Arterial Pressure of 52mmHG). She was bolused with Ringers' Lactate and gelafundin and was put on inotropes. We did a right

Hemicolectomy and because of the hemodynamic instability we decided to give her an end ileostomy. Postoperatively she was admitted into the intensive care unit for cardiopulmonary support where she was inotrope-dependent for 24 hrs. She was discharged from Intensive Care Unit on day 3. The rest of her post op recovery was uneventful and was eventually discharged from hospital on day 8 post operatively. She had closure of ileostomy 16 weeks later.

## Discussion

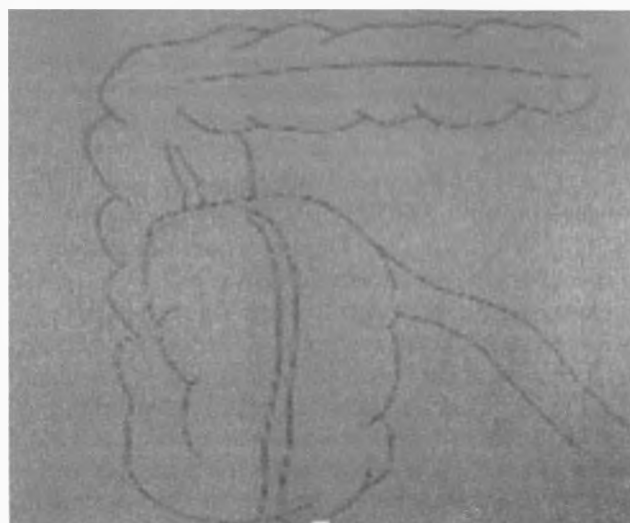
Cecal volvulus is characterised by the axial twisting that occurs involving the cecum, terminal ileum and ascending colon (Figure 1a).<sup>4</sup>

Figure 1a: *Axial twist.*



Cecal bascule is a variant of this condition associated with the upward and anterior folding of the ascending colon on itself and this accounts for 10% of all cases of cecal volvulus (Figure 1b).

Figure 1b: *Bascule.*



Our patient had the axial type of cecal volvulus.

These two variants tend to present with acute intestinal obstruction. Cecal volvulus is reported to

account for less than 1% of all cases of intestinal obstruction and 25-40% of colonic volvulus.<sup>5</sup> A mobile cecum, which is due to some degree of malrotation, is a prerequisite for volvulus to occur and is found in 10-15% of cadavers.<sup>6</sup> There is however a 40 fold difference between the incidence of mobile cecum and occurrence of cecal volvulus suggesting that other than anatomical susceptibility, there are other factors involved in the development of cecal volvulus. Clinical series have reported that 23-53% of patients with cecal volvulus have a history of prior abdominal surgery.<sup>7</sup> This led to the postulation that postoperative adhesions contributes to the formation of fixation points and fulcrum of rotation for the mobile right colon thereby promoting volvulus development.<sup>8</sup> The incidence of cecal volvulus also increases significantly in pregnancy. However it must be emphasised that despite this relative increase in incidence of cecal volvulus in pregnancy, intestinal obstruction, in general, during pregnancy remains a very rare condition. In one study done in Zimbabwe the incidence of intestinal obstruction in pregnancy was 1 in 7179 and there has not been any reports of cecal volvulus in pregnancy in the series that included over 93000 deliveries.<sup>14</sup>

When cecal volvulus occurs in pregnancy, the incidence is greatest at times of rapid uterine size changes, especially from 16 to 20 weeks when the uterus become an intraperitoneal organ, from 32 to 36 weeks when as the foetus enters the pelvis and in the puerperium when the uterus rapidly contracts.<sup>15</sup> In pregnancy the uterus displaces the mobile cecum upwards thus predisposing it to torsion, and in the puerperium the rapid uterine contraction will leave an increased intraperitoneal space that also can allow twisting of the already displaced cecum. Additional conditions such as high fibre intake, adynamic ileus, chronic constipation and distant colonic obstruction have been implicated in cecal volvulus formation in anatomically susceptible people, presumably through cecal displacement, hyperperistalsis and colonic distension.

### **Clinical presentation.**

The clinical presentation of cecal volvulus is determined by the pattern, severity, and duration of the intestinal obstruction. The patterns of presentation are broadly categorised as recurrent intermittent, acute obstruction, and acute fulminant patterns.<sup>9</sup>

The recurrent intermittent pattern has been referred to as the "mobile cecum syndrome". The patients present with recurrent symptoms of generalised or localised right lower quadrant abdominal pain, distension and vomiting which tend to be relieved after passage of flatus. These symptoms can easily be attributed to the normal discomforts of pregnancy thus resulting in delayed diagnosis. This clinical presentation has been reported in about 50% of patients before onset of acute

obstruction. In the acute obstructive pattern the presentation can be indistinguishable from acute uncomplicated small bowel obstruction. On physical examination, however, a dilated tender tympanic cecum may be palpable thus helping distinguish it from small bowel obstruction. If left untreated this acute obstructive pattern can progress to the fulminant presentation when strangulation and perforation of the cecum occurs. The patients, as in the case presented here, will present with severe abdominal pain, peritonitis, dehydration and hemodynamic instability. Again in pregnant women this clinical picture can lead a clinician to suspect some obstetric complications such as Abruption placenta or a ruptured uterus. This was the scenario in the case we are presenting here.

Laboratory evaluations, though they are neither sensitive nor specific in diagnosis of cecal volvulus, may reflect the fluid and electrolyte deficiencies and inflammatory or infectious changes related to the obstructive process.

### **Diagnostic imaging.**

Radiological abnormalities are identifiable in nearly all patients with acute cecal volvulus. The diagnosis of cecal volvulus can be made with abdominal plain x-rays which has a sensitivity of 95%. There is usually a characteristic coffee bean deformity that may be seen directed towards the left upper quadrant.<sup>10</sup> This may be associated with distended loops of small bowel localised lateral to the dilated cecum and absence of air in the distal colon. However in pregnancy, there is a general reluctance to request abdominal x-rays for fear of foetal radiation exposure. Unfortunately this leads to delays in diagnosis of this rare and potentially fatal condition. The foetal risk from one or two exposures is minimal because the total dose from three abdominal films is 182mrad, which is a small dose unlikely to cause any clinical problems.<sup>11</sup> Carcinogenesis and teratogenic complications occur after exposure to 1 rad and 20 rad respectively.<sup>12</sup> Thus it will be justified and strongly recommended to request x-rays in pregnancy when there is a high index of suspicion of intestinal obstruction, because of the significant maternal and foetal mortality associated with undiagnosed or delayed diagnosis of intestinal obstruction in pregnant patients. The potential benefit of the x-rays outweighs the risk from radiation exposure.<sup>2</sup>

### **Surgical treatment.**

Surgical treatment of cecal volvulus consist of untwisting the bowel if it is viable, decompressing the distended segment, removing devitalised tissue and preventing recurrence. Given the unusual nature of the disease there are no prospective treatment trials to guide management decisions in these patients. It is generally agreed that when intestinal perforation or gangrene is encountered, the right hemicolectomy should be done. However in the absence of these complications the appropriate extent of the operative therapy remains undetermined.<sup>13</sup> Several non-resection

procedures have been described.

Barium enema detorsion has been noted in sporadic reports. However its success rate is unknown, thus this modality is not usually recommended as a therapeutic option.<sup>13</sup> Colonoscopic reduction has a reported success rate of about 30% but recurrence rate is unknown.<sup>17</sup> Operative detorsion by laparotomy has also been advocated for and where it has been used it had a mortality rate of 0-25% and recurrence rate as high as 70%.<sup>13</sup> Cecopexy is the fixation of the right colon is done by suturing of the cecum and/or ascending colon to parietal peritoneum. Mortality rate in this case has been reported in 0-30% with a recurrence of 0-40%.<sup>5</sup> The other option that has been described is caecostomy tube placement. Its mortality and morbidity is similar to cecopexy.

Right hemicolectomy is the most definitive procedure of cecal volvulus as it eliminates the possibility of recurrences and has become the most popular procedure.<sup>4,16</sup> Proponents for lesser procedures cite increased morbidity and mortality in colectomies related to prolonged operating time and increased magnitude of physiological insult to the patient.<sup>5</sup> Historically, operative mortality associated with colectomy has been higher than the mortality of cecopexy and caecostomy. However a confounding factor in outcomes reported by some of these retrospective studies is that resection is necessitated in some patients as a result of bowel strangulations, therefore the morbidity and mortality reported may reflect patient differences rather than treatment related differences.<sup>4,7</sup> Advances in peri-operative care in the last decade have improved the outcome.<sup>4</sup> The majority of patients, regardless of bowel perforation or strangulation can be managed successfully with right hemicolectomy and primary ileo-colic anastomosis. However in very sick patients, as in the case presented here right hemicolectomy and end ileostomy would be the appropriate procedure.<sup>4</sup> In pregnancy there is marked displacement of the cecum, which may predispose to recurrence so resection of bowel is the best procedure to undertake.<sup>10</sup> Caesarean section using a lower midline vertical incision should be considered to facilitate full inspection of bowel and subsequent resection.<sup>10</sup>

### Conclusion

Cecal volvulus is a very rare condition which occurs when there is mal-fixation of the cecum due to some degree of malrotation. Pregnancy is one of the factors that contributes to development of cecal volvulus due to the upward displacement of the cecum. As illustrated in this case, diagnosis in pregnancy is usually delayed because presentation may be attributed to the usual discomforts of pregnancy. Abdominal x-rays should be requested whenever there is a high index of suspicion of intestinal obstruction. Right hemicolectomy is the definitive treatment of cecal volvulus as it eliminates

any possibility of recurrence.

### References

1. Anderson A, Berghdhal L, Linden W. Volvulus of the cecum. *Ann Surg* 1975;181:876-80.
2. Perdee P W, Johnson HW, Stafford PW. Intestinal obstruction complicating pregnancy. *Am J Surg* 1992;164:384-8.
3. Lopez Carral JM, Esen UI, Chandrashekar MV, et al. Volvulus of right colon in pregnancy and puerperium. *Obstet Gynecol* 1958;12:367-76.
4. Madiba TE, Thompson SR. The management of cecal volvulus. *Dis Colon Rectum* 2002;45:264-7.
5. O'Mara CS, Wilson TH, Stanesifer C et al. Cecal volvulus. Analysis of 50 patients with long term follow-up. *Ann Surg* 1979;189:725-31.
6. Weiss BD, Cecal Volvulus. A diagnostic and therapeutic challenge. *Postgrad Med* 1982;72:189-94.
7. Tejler G, Jiborn H. Volvulus of the Cecum. Report of 26 cases and review of literature. *Dis Colon Rectum* 1988;31:445-9.
8. Rabinovici R Simansky DA, Kaplan O et al. Cecal Volvulus. *Dis Colon Rectum* 1990;33:765-9.
9. Friedman JD, Odland MD, Bubrick MP. Experience with colonic volvulus. *Dis Colon Rectum* 1989;32:409-16.
10. Montes H, Wolf J. Cecal volvulus in pregnancy. *Am J Gastroenterol* 1999;94:2254-5.
11. Kereiakes JG, Rosentstein M, CRC Handbook of Radiation doses in nuclear medicine and Diagnostic X-ray. Boca Raton: CRC Press 1980.
12. Cunningham FG, Gant NF, Leveno KJ et al. General consideration and Maternal evaluation. *Williams Obstetrics* 21<sup>st</sup> ed. New York:McGraw Hill;2001:1143-58.
13. Consorti ET, Liu TH. Diagnosis and Treatment of cecal volvulus. *Postgrad Med J* 2005;81:772-6.
14. Muguti GI, Intestinal obstruction during pregnancy and the puerperium at Mplilo Central Hospital. *J R Col. Surg Edinb* 1988;33:156-8.
15. Harer WB, Harer WE. Volvulus complicating pregnancy and puerperium. *Obster Gynecol* 1958;12:367-76.
16. Habre J, Sautot-Vial N, Marcotte C, Benchimol D. Cecal Volvulus. *Am L Surg* 2008;196:e48-e49.
17. Orchard JL, Mekha R, Khan H. The use of Colonoscopy in the treatment of colonic volvulus: Three cases and review of literature. *Am J Gastroenterol* 1984;79:864-7.



This work is licensed under a  
Creative Commons  
Attribution – NonCommercial - NoDerivs 3.0 License.

To view a copy of the license please see:  
<http://creativecommons.org/licenses/by-nc-nd/3.0/>

This is a download from the BLDS Digital Library on OpenDocs  
<http://opendocs.ids.ac.uk/opendocs/>