

# The CENTRAL AFRICAN JOURNAL OF MEDICINE

Dr. DAVID LIVINGSTONE

ANNUAL CONGRESS, MEDICAL ASSOCIATION, S. RHODESIA  
19th SEPTEMBER to 21st SEPTEMBER, 1958, at QUE QUE

Vol. 4, No. 8.

## CONTENTS

AUGUST, 1958

### ORIGINAL ARTICLES

The African and Plastic Surgery	<i>G. E. Clayden</i> - - - -	317
Oxycephaly in an African Child	<i>R. G. M. Whittaker</i> - - -	323
Bone and Joint Tuberculosis in Kenya	<i>W. H. Kirkaldy-Willis</i> - -	324
Practice of Tropical Medicines	<i>Sir Philip Manson-Bahr</i> - -	330
Prevention of Maternal Death	<i>D. Llewellyn-Jones</i> - - -	340
Personal Reminiscences of Fort Salisbury S. Rhodesia	<i>F. Rand</i> - - - - -	345

### EDITORIALS

Mushroom Poisoning		347
Living Longer		348
Home or Hospital		349
Fairways Homes for the Aged		350
Bursaries for Medical Study (The Malvern Trust) - - - - -		350
Fourth Congress of S.A. Paediatric Association - - - - -		351
Msasa Hospital, Salisbury - - - - -		351
Medical Congress - - - - -		353
Salisbury Clinical Club (Gargoylism) -		354
Dental Association of S. Rhodesia - -		356
Correspondence - - - - -		357
In Rhodesia Then - - - - -		358
Book Reviews - - - - -		359
The Journal Library - - - - -		360
Annual Medical Congress—Programme		361
Latest Pharmaceuticals - - - - -		362

PUBLISHED MONTHLY, ANNUAL SUBSCRIPTION £2 2s. 0d.

Registered at the General Post Office as a Newspaper.

## Bone and Joint Tuberculosis in Kenya

BY

W. H. KIRKALDY-WILLIS,  
M.A., M.D., F.R.C.S. (Ed.)

Senior Surgeon, Kenya Medical Department.  
Orthopaedic Surgeon, King George VI Hospital, Nairobi.

### INTRODUCTION

One-third of the beds in the African orthopaedic unit of 120 beds in Nairobi are occupied by patients suffering from bone and joint tuberculosis. An attempt to treat these conditions was first made 12 years ago. It has been continued with all possible thoroughness ever since at a gradually increasing *tempo*. By coincidence it was possible to start the treatment of bone and joint disease before that for pulmonary lesions.

Throughout Kenya the treatment of tuberculosis in African patients is a problem of considerable magnitude. The writer supposes that over the next ten years this will be the problem that will exercise medical men throughout the continent of Africa in an increasing way more than any other.

It is therefore of fundamental importance not only to treat tuberculosis in all its forms in African patients, but even more to elaborate methods of treatment that are most suitable for Africa. This latter implies that operative techniques must be made so simple that they can be carried out successfully in provincial centres as well as in the capital cities of each territory.

### DIAGNOSIS

In the vast majority of cases of bone and joint tuberculosis in Kenya the disease is so far advanced on the patient's admission that gland or joint biopsy or prolonged observation is not necessary before diagnosis can be made.

There are, however, certain pitfalls. A low grade infective arthritis can produce X-ray changes indistinguishable from tuberculosis. Fortunately in most such cases the treatment is almost identical. Osteomyelitis, subacute or chronic in nature, can also be misleading. But here the diagnosis becomes increasingly apparent in X-ray plates over one to two months, the main changes being in the bone at some little distance from the joint. A confusing factor is that spinal tuberculosis may on occasion pro-

duce more sclerosis than erosion. It is wise in every case to exclude brucellosis. This may well at the onset be confused with a sclerosing type of tuberculosis in a spine or hip. Framboesia may produce a clinical and X-ray picture indistinguishable from tuberculosis, and with sinuses. The writer has seen three such cases, with a positive Kahn reaction, disguised as tuberculosis at the onset, but cured by the administration of arsenicals and bismuth.

### TYPE OF DISEASE

In approximately 5 per cent. of all cases there is concomitant active pulmonary disease. Of the remaining 95 per cent., approximately 10

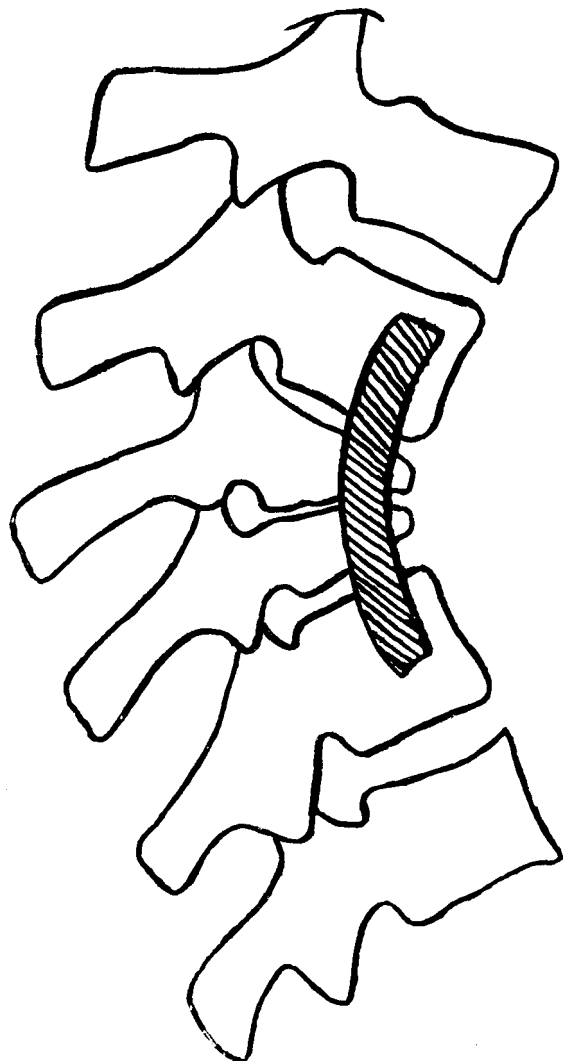


Fig. 1--Anterior spinal fusion.

per cent. show minimal X-ray signs of previous pulmonary disease. The writer believes that all cases of skeletal tuberculosis in this country have had a minor attack of pulmonary disease. Many of these have recovered without treatment because they have never been diagnosed as such. Fairly advanced disease with marked erosion of bone is observed in 90 per cent. of all cases seen. Yet they respond rapidly to treatment. A long history of disease is given by 5 per cent. Another 5 per cent. first come with very advanced disease for which little can be done; their downhill course is rapid. In effect, the prognosis with simple but adequate treatment is extremely good in 90 to 95 per cent. of all cases.




Fig. 2—Tuberculous spine before operation.

#### TREATMENT

*General.*—Rest, both local and to the system, is undoubtedly beneficial, but can be overdone. African patients do not stand operation well after months of complete bed rest. Carefully controlled movements to normal joints appear beneficial to the general progress of the patient. Prolonged and complete immobilisation of a joint results in muscle wasting, osteoporosis and premature epiphyseal fusion. It is our practice to immobilise the spine on a plaster bed. Here the immobilisation is of necessity often incom-

plete. It is not unusual for a patient to arise from his bed and walk during the night watches, whilst the dresser is asleep or round the corner having a "quick one." Other joints are immobilised or placed on extension only if the disease is so recent that we anticipate as the end result a painless joint with a useful range of movement.

It is of course of added importance in Africa to deal with concomitant anaemia, hookworm, roundworm or schistosomiasis. The diet is of great importance amongst people whose diet is in the main deficient since early childhood. It is not unusual to encounter kwashiorkor in African tuberculous subjects. The mental accord that exists between the good physician and his patient plays perhaps the greatest part of all in the latter's recovery. The writer finds that when, by any means, he can make the patient smile and laugh, the battle towards recovery is almost won. Real laughter is in fact of greater importance than the most carefully planned and executed operation.

*Chemotherapy.*—Here we have found that the most efficacious treatment for adults is streptomycin, 1 gm. daily, with isoniazid, 200 mg. three times a day, with correspondingly smaller doses for children. This is continued for at least three and at the most six months. It would appear that at present the response to chemotherapy amongst Africans is greater than amongst Europeans in Britain. Possibly this is, alas, a passing phase. Of physical methods of treatment, we rely on chemotherapy more than on anything else. But this treatment is not effective in several ways. (1) Streptomycin cannot penetrate an area of disease that is avascular or surrounded by a wall of fibrous tissue. (2) Tuberculous pus, under chemotherapy, should now be regarded as "laudable pus" and removed. In the spine the disease can spread up and down through an abscess. (3) Healing cannot well take place in the presence of a tuberculous sequestrum. Such a sequestrum is due to thrombosis of arterioles and venules. Thrombosis is of frequent occurrence in tuberculosis. In all these instances it is necessary to operate, in order to improve the vascular supply so that chemotherapy can permeate every area of disease, to remove pus, and to remove sequestra. It is possible that the use of corticosteroids in a careful manner may in future reduce the need for operation to some extent.

*Operative Treatment.*—(1) The first place for operation is, as indicated in the previous paragraph, to open up the path for chemotherapy to

all areas of disease and to remove pus and sequestra. Chemotherapy has, by saturating the surrounding tissues with drugs that are lethal to the tubercle bacillus, rendered such procedures relatively safe.

(2) In the vast majority of African patients on admission the affected joint is so disorganised that even when the general and local infection

treatment frequently occupied one to two years. It is now possible under a streptomycin "umbrella" to telescope the treatment and effect an immediate cure in a much shorter period of time. It is at the present time our practice to operate once and for all after two to three months of rest, immobilisation and chemotherapy. At operation we set out to do two

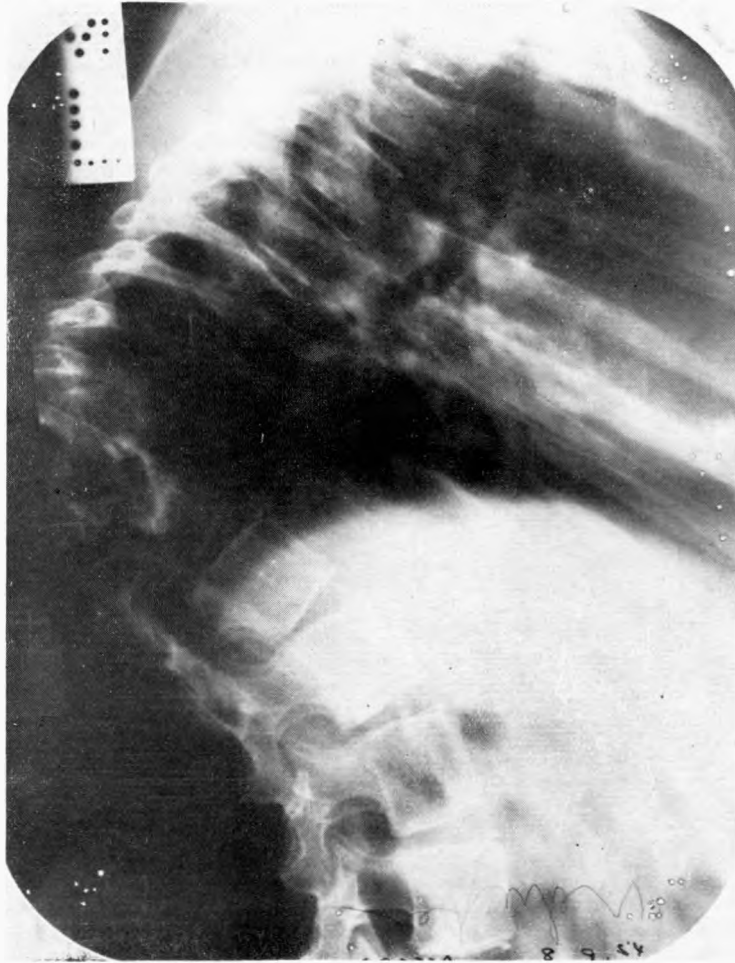

Fig. 3—Tuberculous spine six months after antero-lateral body to body fusion.

is under control a severe mechanical joint defect remains. This results in a painful and unstable joint with a range of movement so small as to be useless. The solution to this problem is in most cases an arthrodesis.

(3) Until recently it has been the reasonable practice all over the world to treat skeletal tuberculosis conservatively until it became quiescent. At this stage arthrodesis was considered when advisable. This programme of

things at one time: (a) to remove fibrous tissue and avascular tissue, to evacuate pus and remove sequestra; and (b) to deal with the mechanical defect by arthrodesing the joint. By such means it is possible in most cases to reduce the time in hospital to six to nine months. Of this time, two to three months are pre-operative and three to six months post-operative.

*Operative Details.*—(1) The Spine: In practice it has never yet been necessary to fuse the

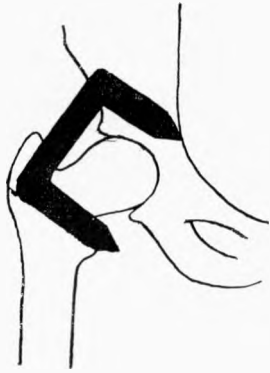

Fig. 4—Staple arthrodesis hip.

cervical spine for tuberculosis, nor to decompress the cervical spine for paraplegia.

Until three or four years ago it was our practice to perform a posterior fusion of the thoracic spine in nearly every case of tuberculous disease in that area. More recently we have found that (a) a fusion on the convexity of the spinal curve is often only partially successful; (b) it is advisable to evacuate the pus from a paravertebral abscess in order to prevent spread of the disease; and (c) it is possible to fuse the thoracic spine at the same time as making an attempt to remove the cause of paraplegia. For these reasons we have set out to

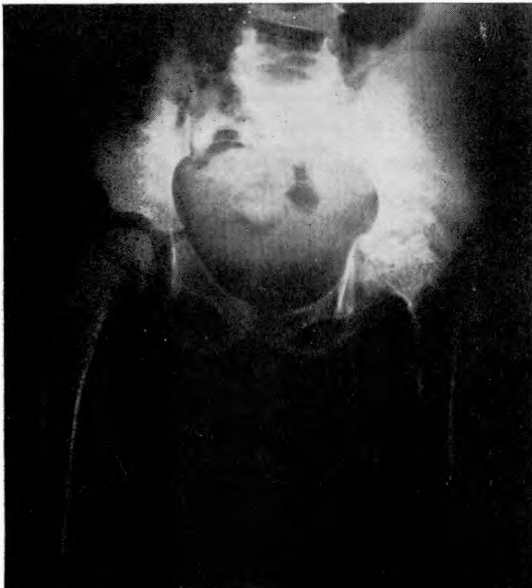

Fig. 5—Tuberculous hip before operation.

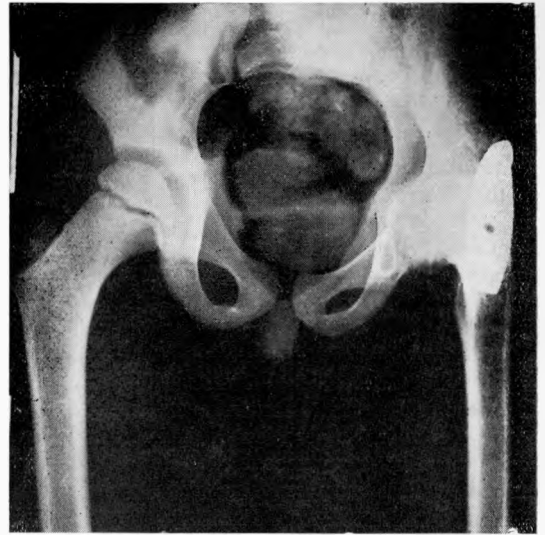


Fig. 6—Tuberculous hip three months after fusion.

undertake an anterolateral spinal fusion from a healthy vertebral body above the site of disease to a healthy body below it in all cases of thoracic disease that require arthrodesis (Figs. 1, 2, 3). The approach is essentially that recommended by Seddon, Griffiths and Roaf for the operation of anterolateral decompression. Any extraspinal abscess is evacuated. A lateral window is made to expose the dura in cases of paraplegia and the cause removed as recommended by Seddon, Griffiths and Roaf. The vertebral bodies are then rawed and one or more rib grafts are inserted from a cleft in healthy bone above to a cleft in healthy bone below the site of the lesion. Rib chips are placed anterolaterally around this.

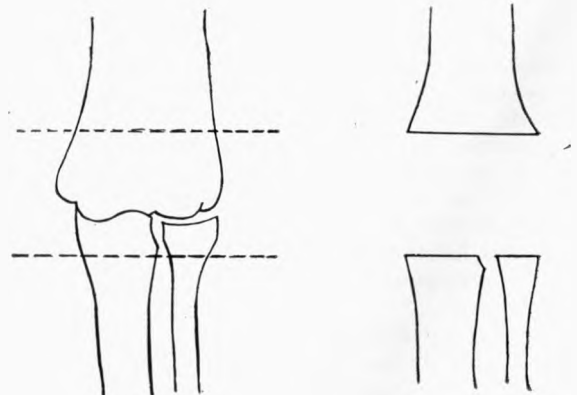


Fig. 7—Elbow before and after excision.

In lumbar spinal disease a careful posterior fusion is done, using chip grafts cut from the tibia with a chisel as recommended by Osmond Clarke.

(2) Paraplegia: In Kenya Africans 90 per cent. of all cases of Pott's paraplegia occur early in the disease. The 10 per cent. of cases occurring after many years do not respond well to treatment, the spinal changes being due to compression by bone or to traction over a bony spur. In paraplegia of early onset there is dramatic improvement in 20 per cent. of cases after operation (antero-lateral decompression); in a further 30 per cent. of cases there is gradual recovery over three to four months which appears to be due to the operation; in a further 30 per cent. there is slow recovery over six to seven months which may or may not be due to the

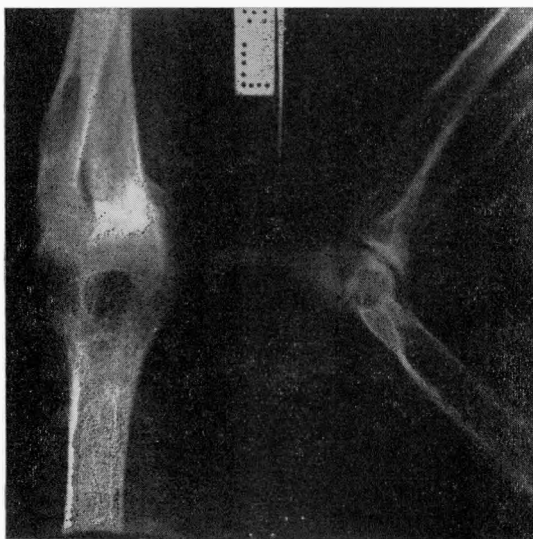

Fig. 8—Tuberculous elbow before operation.

operation; in 20 per cent. there is no recovery, the cause of paraplegia presumably being vascular thrombosis. In African patients it is important to operate if conservative treatment fails to produce any recovery of muscle power in two to three months, simply because it is not yet possible to differentiate between paralysis caused by an abscess, by granulation tissue, by an intraspinal sequestrum or by vascular thrombosis.

(3) The Hip: We have tried every known operative method over 10 years of fusing the tuberculous hip. It is desirable here to fuse the hip by a method that can be used by the general surgeon, that does not shock the patient

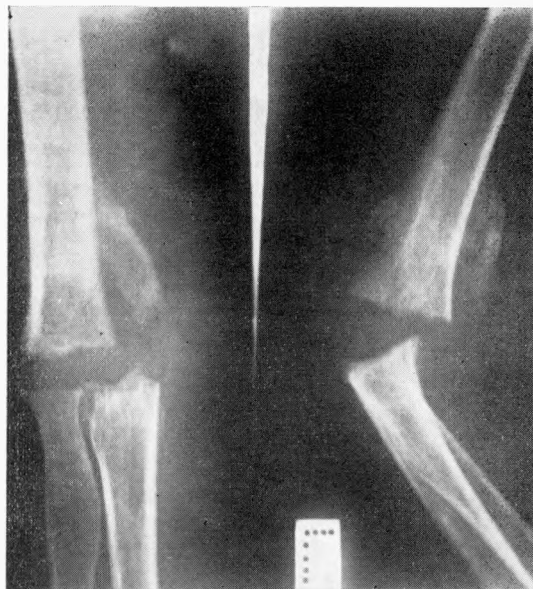

Fig. 9—Tuberculous elbow two months after excision of the joint.

unduly, and that produces fusion in every case. In our hands the most satisfactory method is an intra-articular arthrodesis, done through an anterior Smith-Petersen incision (Figs. 4, 5, 6). After raving of the acetabulum and femoral head and careful reapposition of the bones on either side of the joint, internal fixation is maintained by means of a large staple. Complete fusion has been obtained in every case over the past four years by this method, which will shortly appear in detail in an American number of *The Journal of Bone and Joint Surgery*.

(4) The Elbow: In every case in which the elbow joint is involved we have found that exci-

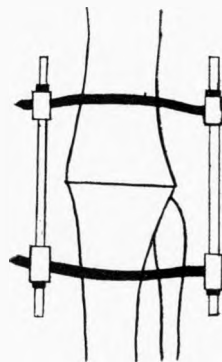


Fig. 10—Key arthrodesis knee.

sion of the joint, followed by three to four months of intensive physiotherapy, gives excellent results (Figs. 7, 8, 9).

(5) The Knee: Here the arthrodesis first described by J. Albert Key and popularised by Charnley is the operation of choice (Fig. 10).

#### FOLLOW UP

We have since 1950 made a serious attempt to follow up all our cases. This attempt is only about 75 to 80 per cent. successful, but indicates that 90 per cent. of all our cases seen repeatedly remain permanently well. The inability to find work or lack of incentive to work, with resulting low standards of living and of diet, is in the remainder largely responsible for the rate of relapse.

#### CONCLUSION

This problem is undoubtedly the most fascinating of all African orthopaedic problems. It entails an understanding of the mind of the patient and of medicine as well as of surgical technique. All operative techniques are sufficiently simple for their performance in the smaller centres, except for the operation of antero-lateral decompression and antero-lateral thoracic body to body fusion.

#### REFERENCES

1. GRIFFITHS, D. L., SEDDON, H. J. & ROAF, R. (1956). Potts Paraplegia. Oxford University Press. London, Cumberlege.
2. KIRKALDY-WILLIS, W. H. (1945). *Lancet*, 2, 53.
3. KIRKALDY-WILLIS, W. H. & MBUTHIA, A. S. (1946). *E. Afr. med. J.*



This work is licensed under a  
Creative Commons  
Attribution – NonCommercial - NoDerivs 3.0 License.

To view a copy of the license please see:  
<http://creativecommons.org/licenses/by-nc-nd/3.0/>

This is a download from the BLDS Digital Library on OpenDocs  
<http://opendocs.ids.ac.uk/opendocs/>