

The CENTRAL AFRICAN JOURNAL OF MEDICINE

Dr. DAVID LIVINGSTONE

Vol. 1. No. 5

SEPTEMBER, 1955

CONTENTS

ORIGINAL ARTICLES

The Art of Diagnosis	<i>D. Hunter</i> - - - - -	207
Tetanus Neonatorum Treated with Chlorpromazine	<i>M. Gelfand</i> - - - - -	216
Volvulus of the Stomach	<i>W. Shepherd Wilson</i> - - -	218
Blackwater Fever in an African Child	<i>H. F. Theron</i> - - - - -	220
Africa, But Not So Dark	<i>W. Robertson</i> - - - - -	221
Chemotherapy in Pulmonary Tuberculosis	<i>A. I. L. Turnbull</i> - - - -	228
Pulmonary Haemosiderosis	<i>J. R. Harries</i> - - - - -	235
Impending Coronary Thrombosis	<i>A. Divaris</i> - - - - -	239
The Right Base	<i>T. Fane Tierney</i> - - - -	243
African Vital Statistics	<i>J. R. H. Shaul</i> - - - - -	246
The Management of Syphilis	<i>R. R. Willcox</i> - - - - -	250
The Nganga	<i>M. Gelfand</i> - - - - -	255

EDITORIALS

Rugby Football Injuries		259
The Age of Retirement		261
The Quack		262
Correspondence - - - - -	Banquet in Honour of Lord Malvern and Professor Drennan - - -	263
The Journal Library - - - - -	Annual Congress of the Medical Association of S. Rhodesia - -	264

Pulmonary Haemosiderosis

A REPORT OF A CASE OCCURRING IN AN AFRICAN

BY

J. R. HARRIES,

M.D., M.R.C.P., D.T.M. & H., D.C.H.,

(King George VI Hospital, Nairobi.)

Pulmonary haemosiderosis is produced by conditions causing intra-pulmonary haemorrhage. There are three clinical types recognised: (1) idiopathic in children; (2) associated with mitral stenosis; (3) following long-standing left ventricular failure.

(1) Idiopathic haemosiderosis was first described by Ceelin (1931). It usually occurs in children under the age of 16 years, but Tait (1952) has described a case in a male aged 31 years. The condition which has been reviewed by Wyllie (1948) consists of sudden recurrent attacks of fatigue, cyanosis, pallor, increasing dyspnoea and tachycardia. Cough is troublesome and often associated with blood in the sputum or vomit. Abdominal pain is not uncommon. The attacks are febrile, the fever lasting from two to several days. Jaundice, enlargement of the liver and spleen and clubbing of the fingers have been described. The blood picture shows a hypochromic anaemia, a raised reticulocyte count and a polymorphonuclear leucocytosis (Wyllie, 1948).

The radiological changes consist of pulmonary mottling, chiefly in the middle and lower zones, of a coarse type except in adult cases, and hilar enlargement. Occasionally nodulation of a silicotic type and partial lobar atelectasis are seen (Ellman, 1951).

(2) Cases associated with mitral stenosis were first mentioned in 1858 by Virchow. Important contributions on the aetiology and pathology have been made by Scott *et al.* (1947), Laubrey *et al.* (1948), Lendrum *et al.* (1948) and Ellman *et al.* (1951). The miliary lesions in the lungs are localised in the alveoli and alveolar ducts and consist of accumulations of siderophages (heart failure cells) with a surrounding fibrotic capsule. The fibrotic capsule interferes with the lymphatic drainage from the alveoli so that the lesions remain fixed and constant (Lendrum, 1950). It has been suggested that the localisation of the lesions is due to haemorrhages occurring at the site of varicosities between the pulmonary and bronchial circulations, and

that these are due to differences between the pulmonary and bronchial circulatory pressures (Lendrum, 1950). Doubt has been thrown on the necessity to postulate varicosities between the pulmonary and bronchial circulation in order to localise the collection of siderophages. Magarey (1951) has shown that intra-bronchial injection of blood into rats produces typical localised collections of siderophages in the alveoli and alveolar ducts similar to those found in cases of pulmonary haemosiderosis.

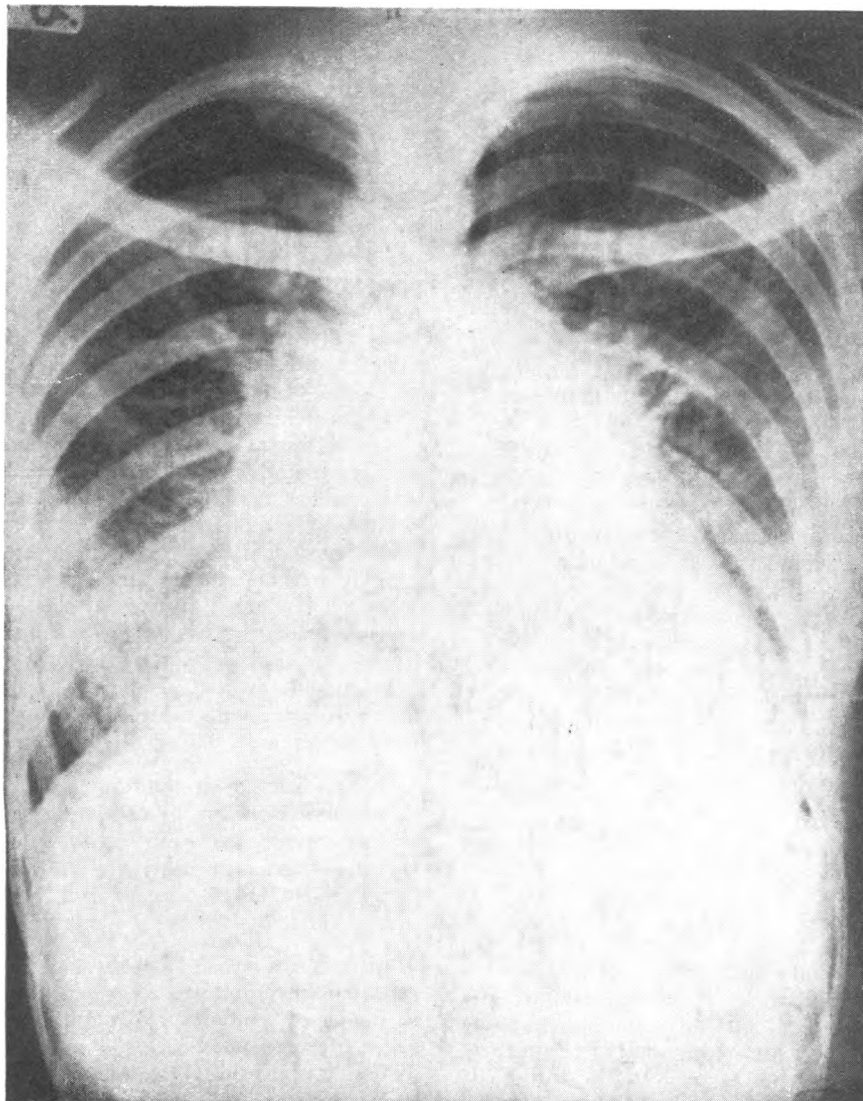
The pulmonary pressure may not be high (Ellman, 1951). The right ventricle is always enlarged. Haemosiderosis is preceded by the development of pulmonary oedema, and whereas phagocytosis of red cells is effective in the normal lung, this is not so in the oedematous lung (Strassman, 1944). A further factor is that haemosiderin is insoluble in the alkaline medium of pulmonary oedema (Strassman, 1944). Weitzman (1952) points out that infarcts in mitral stenosis with pulmonary oedema are adequately removed and poses the question why under similar conditions haemosiderosis occurs. He quotes Ellman's (1951) suggestion that the deposits of red blood cells occur too quickly to be removed and considers the possibility of a primary disease of elastic tissue. The case described by Fisher (1952) agrees with the hypothesis that pulmonary oedema precedes the development of haemosiderosis, for in his case the appearance of typical radiological changes took two years.

The *post-mortem* findings of collections of siderophages in the alveoli are not rare, but it is uncommon to find radiological changes. Haemosiderosis in itself does not influence the prognosis in mitral disease and is not a contra-indication to valvotomy (Weitzman, 1952).

In haemosiderosis complicating mitral disease repeated haemoptyses are usual. The diagnosis is made by radiological examination, the presence of siderophages in the sputum (Grumpert, 1947), and by lung puncture (Laubrey, 1948).

The radiological picture is constant after the changes have become established. The lung fields show miliary shadowing characterised by the following features:—

- (a) Distribution mainly in the middle and lower zones, the apices being spared.
- (b) Regularly disseminated discrete dense miliary nodules, 1-3 mm. in diameter, with a central relative translucency superimposed on a fine reticular background.



X-ray of the chest shows marked cardiac enlargement towards the right and to a lesser degree to the left. There are fine mottled opacities in both lungs, most marked in the middle and lower zones. The hilar regions are prominent and the pulmonary vessels enlarged.

(c) Diminished translucency of the lung fields due to pulmonary oedema.

(d) Increased hilar shadows (Ellman, 1951).

It is possible that some cases of intralveolar ossification (Elkeles, 1947) and chronic miliary tuberculosis (Waldenstrom, 1948) are, in fact, cases of pulmonary haemosiderosis.

(3) A few cases of haemosiderosis have occurred with long-standing left ventricular failure unassociated with valvular disease. The pathology is similar to that of the mitral type. The suggested mechanism is that with remittent left ventricular failure there are recurrent falls in systemic pressure and a similar reduction of the gradient at the anastomosis. The pulmonary pressure suffers less or no fall and so is at a relatively raised pressure compared with that of the bronchial arteries (Lendrum, 1950).

CASE REPORT

Male Mkamba, aged 32 years, was admitted with shortness of breath, cough and a history of repeated haemoptyses for the previous nine months. Examination showed evidence of congestive cardiac failure with engorgement of the neck veins, an enlarged tender liver and diffuse crepitations at both lung bases. His pulse was irregular due to extrasystoles. The apex beat was in the sixth space, one inch within the anterior axillary line. The first sound at the apex was loud and abrupt and was followed by a systolic murmur, maximal at this point. A mid-diastolic and presystolic rumbling murmur were heard internal to the apex. The pulmonary second sound was split. There were no aortic or pulmonary murmurs.

INVESTIGATIONS

An X-Ray of the chest showed marked cardiac enlargement towards the right side and to a lesser degree to the left. There were fine mottled opacities in both lungs, most marked in the middle and lower zones. There was hilar enlargement and enlargement of the pulmonary vessels (Fig.).

Screening revealed a large left auricle, right ventricle and pulmonary conus.

The *electrocardiogram* showed right ventricular strain. The ST segment was depressed and the T waves inverted in CR1 and CR4.

Sputum.—There were numerous siderophages. No acid fast bacilli on direct examination or culture.

Stomach Washout.—No acid fast bacilli on direct examination or culture.

Mantoux Reaction.—1/1,000 negative; 1/100 positive. E.S.R.—3 mms. first hour (Wintrobe).

Hb., 82%; *WBS.*, 5,600; *Polymorphs*, 62%; *Lymphocytes*, 35%; *Eosinophils*, 2%; *Basophils*, 1%.

Urine.—Trace of albumin. No ova.

Stool.—No ova or cysts.

PROGRESS

The patient was treated with digitalis, mersalyl intramuscularly twice weekly and a moderate restriction in the fluid intake.

After two months in hospital, when the signs of failure had subsided and he was able to walk about without breathlessness, he was discharged from my care on a maintenance dose of digitalis.

DISCUSSION

This case presented little difficulty in diagnosis in view of the presence of mitral stenosis and miliary mottling and numerous siderophages in the sputum. Miliary tuberculosis which is the only common cause of miliary mottling in Africans is rare in association with mitral stenosis. In South and Central Africa pneumoconiosis has to be considered. Bilharziasis, tropical pulmonary eosinophilia (Weingarten's syndrome) are occasionally encountered. Carcinomatosis occurs rarely in Africans and sarcoidosis very occasionally.

(1) *Acute miliary tuberculosis* differs radiologically from haemosiderosis in that the apices are not spared and hilar enlargement is not necessarily marked. Pyrexia is invariably present and the Mantoux reaction is usually positive. The blood sedimentation rate is always raised.

(2) *Bilharziasis* may show miliary shadows consisting of (a) soft discrete spherical nodules of uniform size about 1 mm. diameter usually in the lower lobes; (b) scattered linear-shaped calcified foci in the upper lobes; (c) increased striations; (d) enlarged and intensified hilar shadows (Mainzer, 1939). The lung changes are usually associated with a cirrhotic liver and an enlarged spleen.

Miliary shadows may also occur in the invasive stage of bilharziasis associated with pyrexia, malaise, anorexia and cough. The spleen is enlarged and the blood shows a marked eosinophilia (Gelfand, 1951; Ritchkin and Gelfand, 1954). This picture is probably of an allergic nature and closely related to tropical pulmonary eosinophilia.

(3) *Tropical Pulmonary Eosinophilia*.—The radiological changes, if of miliary type, consist of prominent bronchial striations and mottling of the lung fields maximal at the hila and bases. The shadows are round, poorly defined at the edges with a maximum diameter of 5 mm. The blood consistently shows an eosinophilia and the E.S.R. is always raised. General symptoms consist of malaise, fever, coryza with a dry cough, worse at night. This is followed in from one to four weeks by a bronchitic phase which may last from months to years. Eventually an asthmatic condition ensues. The response to organic arsenicals is dramatic (Crofton *et al.* 1952, Seaton, 1953).

SUMMARY

(1) The aetiology and pathology of the types of pulmonary haemosiderosis are discussed.

(3) The differential diagnosis of pulmonary haemosiderosis in East Africa is discussed.

(3) The differential diagnosis in East Africa is discussed.

ACKNOWLEDGMENT

I wish to thank the Hon. Director of Medical Services of Kenya for permission to publish this article.

REFERENCES

- Ceelin, W. (1931): In *Henke & Lubarschs Handbuch der Speziellen Pathologischen Anatomie*, III, 3, 20.
- Crofton, J. W., Livingstone, J. L., Oswald, N. C., Roberts, A. T. M. (1952): *Thorax* 7, 1.
- Eckeles, A. (1947): *Proc. Roy. Soc. Med.* 40, 405.
- Ellman, P. (1946): *Brit. Med. J.* 1, 127.
- Fisher, R. E. W., and Makin, R. (1951): *Lancet* 1, 549.
- Gelfand, M.: *Schistosomiasis 1951*, p. 111; Post. Grad. Press, Juta and Co., Capetown and Johannesburg.
- Gelfand, M. (1948): *The Sick African*, 2nd Edition, p. 353. Stewart Printing Co., Ltd., Capetown.
- Grungert, T. E. (1947): *Brit. Med. J.* 2, 488.
- Lendrum, A. C., Scott, L. D., and Park, S. D. S. (1950): *Quart. J. Med.* 19, 249.
- Lendrum, A. C. (1950): *J. Path. & Bact.* 62, 555.
- Lancet* (1952): *Editorial*, 12th May, p. 1005.
- Laubrey, C., Lenegue, J., and Abbas, J. (1948): *Acta Cardiol.* 3, 11.
- Magurey (1951): *J. Path. & Bact.* 63, 729.
- Mainzer (1938): *Trans. Soc. Med. & Hyg.* 32, 253.
- Ritchken, J., and Gelfand, M. (1951): *Brit. Med. J.* 1, 1419.
- Scott, L. W. D., Scott Park, S. D., and Lendrum, A. C. (1947): *Brit. J. Radiol.* 20, 300.
- Seaton, D. R. (1953): *Practitioner* 170, 421.
- Strassman, G. (1944): *Arch. Path.* 33, 76.
- Tait, G. B., and Corridan, M. (1952): *Thorax* 7, 302.
- Waldenstrom (1939): In McLaren's *Modern Trends in Diagnostic Radiology*, p. 86. Butterworths, London.
- Weitzman, D., and Husain, O. A. N. (1952): *Brit. Journ. of Tuberc.* 46, 231.
- Wyllie, W. G., Sheldon, W., Bodian, M., and Barlow, A. (1948): *Quart. J. Med.* 17, 25.



This work is licensed under a
Creative Commons
Attribution – NonCommercial - NoDerivs 3.0 License.

To view a copy of the license please see:
<http://creativecommons.org/licenses/by-nc-nd/3.0/>

This is a download from the BLDS Digital Library on OpenDocs
<http://opendocs.ids.ac.uk/opendocs/>