

**The
Central African
Journal
of
Medicine**

**Supplementary Issue to 1992 Volume 38,
1991 University of Zimbabwe Annual Research Day**

CASE REPORTS

Schistosomiasis of the Testis

F N IHEKWABA

SUMMARY

Bilharzial orchitis is still rare in many countries, and when it presents, difficulties in diagnosis arise. Since it stimulates testicular cancer, misdiagnosis invariably leads to orchiectomy, an unfortunate event in the young patient.

INTRODUCTION

Schistosomiasis rarely affects the testis in man. In Africa, this is usually as a complication of infestation of the lower urinary tract by the *S. haematobium*. Although Dew¹ has reported his early observations on the pathology of the disease, testicular invasion by the schistosome has merited only a few reports during the last 50 years.^{2, 3, 4} Indeed the pathological changes in this organ following infection are still incompletely described.

Bilharzial orchitis may be unilateral or bilateral and there may or may not be involvement of the related epididymis and spermatic cord. In unilateral cases, especially in young people, and in those with bilateral swellings, testicular neoplasm may be suspected and excisional surgery undertaken.

This report presents two cases of schistosomal orchitis simulating testicular neoplasms in young people.

CASE PRESENTATION

Case 1: A.A. (390481) presented at the University College Hospital, Ibadan with a 2-month history of an increasing non-tender left scrotal mass. There were no constitutional symptoms. He denied that he had dysuria or haematuria. He had lived in Ibadan city

*Correspondence to: Department of Surgery
University College Hospital
Ibadan
Nigeria*

all his life and there were no relevant social or family history.

Examination revealed a heavy, solid, knobly left testicular mass. seven centimetres in its long axis along its widest diameter. Testicular sensation was preserved. A small hydrocele was palpable in the lower pole. The overlying skin was normal as also was the right testis and its coverings. There was no clinical evidence of hepatic enlargement and the spleen was about one cm below the left costal margin. No other clinical abnormality could be detected.

Haematological investigation showed a PCV = 25 pc, WBC = 3 500 (with 62 pc neutrophils, 33 pc lymphocytes, 5 pc eosinophils). The blood film showed marked anisocytosis, hypochromasia, poikilocytosis and occasional polychromasia. No malaria parasites were seen. Blood urea was 10 mg/100ml and the serum electrolytes were normal. A mid-stream specimen of urine contained various WBC per high power field and there were 4-5 erythrocytes per hpf. Urine culture yielded no growth. The chest X-ray was normal.

A presumptive diagnosis of a malignant left testicular tumour was made and exploration was performed through a left inguino-scrotal incision.

The dislocated testis showed apparent tumour replacement of normal testicular tissues. Retrograde orchidectomy was performed. The formalised excised specimen measured 6 x 4 x 3 cm with a segment of spermatic cord six centimetres long attached to it. the lower pole of the testis was cystic. The rest of the testis felt firm and the cut surface was replaced by a firm uniformly whitish tissue. No normal testicular architecture was seen.

Microscopy showed extensive replacement of testicular tissue with fibrous tissue, scattered granulomata and numerous calcified schistosome ova. The diagnosis was that of schistosomiasis of the testis.

Cystoscopy revealed multiple vesical papillomata surrounded by patches of haemorrhagic cystitis in the posterior wall and particularly in the trigonal area. The ureteric orifices were not identified. Excretion showed dilatation of the middle one third due to partial obstruction at the level of the pelvic brim. The lower half of the left ureter demonstrated typical beading. The post-evacuation film showed multiple filling defects in the bladder. The patient was treated

Figure 1: Testicular schistosomiasis: Photomicrograph of Testis in Case 1 showing Calcified schistosome ova, scattered granulomata and fibrous tissue replacement of testicular substance.

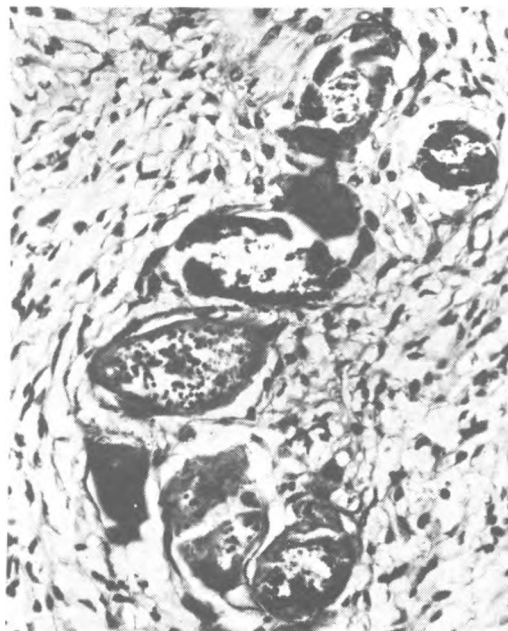


Figure II: Testicular Schistosomiasis: Excretory Urography (Case 1).

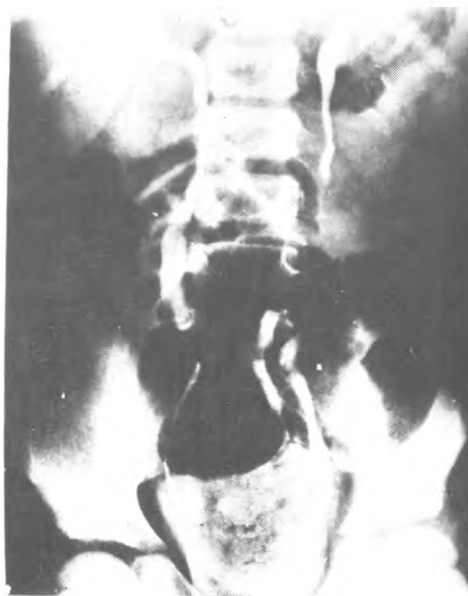
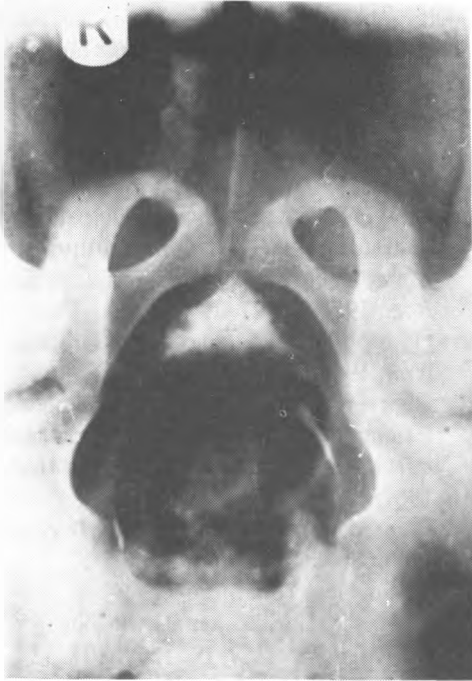
Figure III: Testicular Schistosomiasis: Cystogram
Phase of Figure II.



with niridazole (ambilhar) at a dose of 25 mg/kg daily for seven consecutive days.

Case 2: O.M. aged 16 years complained of a dull aching left testis of four months duration. The testis had been increasing in size for about five months and was now heavier than the right side. He had had a cough for about three weeks which initially responded completely to cough mixtures, but had in the ten days preceding his presentation become "chronic". He had not lost any weight. A right inguinal hernia had been repaired some three years earlier in a private hospital and no testicular swellings had been noted at the time. A chest X-ray which had been ordered by his referring doctor had shown some hazy mottling in the left mid zone only.

Examination revealed a solid, 5 x 3 x 3 cm left testis which was non-tender and did not transilluminate. Sensation was only slightly reduced. The spermatic cords were normal as were the groins. Abdominal examination was unrevealing. A full blood count showed a PCV of 30 pc, WBC 4200/mm² with a normal differential. The MSU was negative on

microscopy. Excretory urography which showed a bifid ureter on the right side was otherwise reported as normal.

A diagnosis of a left testicular tumour was made and a left orchidectomy through a left groin incision was performed. The specimen was reported as schistosomiasis of the left testis. Ambilhar (Niridazole) at a dose of 25 mg per kg body weight and Ampicilin 250 mg four times daily were each exposed for seven days.

DISCUSSION

Schistosomiasis haematobium is endemic in Nigeria. Although not uniformly distributed over the country, Cowper⁵ considered Ibadan where the University College Hospital is situated as the centre of holoendemic area. In a sample survey in the same city, 20 pc of school children between the ages of six and 15 were found to pass the ova of *S. haematobium* in their urine.⁶ However, of the 15,862 surgical biopsies examined by the Pathology Department of this Hospital between 1958-1963, only 0.5 pc showed bilharzial lesions.⁷ Amongst the 102 bilharzial positive biopsies, only one was in the testis in a boy of 12. A similar pattern was observed by Paget and Camain⁴ who in Dakar between 1950-1964 found only two cases with testicular disease out of 340 cases studied, although 160 cases had urogenital involvement. The current true incidence is uncertain but the answer might be found if in endemic areas, digest studies were carried out on all testicular tissue removed at autopsy together with rectal biopsy in all cases of testicular enlargement.

The manifestations of bilharzial infection in man are legion, although a few sites, notably the bladder and ureters, seem to bear the major burden. As testicular involvement is infrequent, even in endemic areas, a painless testicular swelling presenting in an adolescent boy is viewed with considerable suspicion, and urgent investigation to establish a correct diagnosis is of the utmost importance. In malignant cases, failure or delay in diagnosis may lead to early metastatic spread and rapid fatal termination.

The infecting organism in the majority of urinary cases in Africa is *S. haematobium*. Most of this is subclinical invasion by *S. Mansoni* is rare. Steinberger⁹ recorded a single case of infarction of the testicle due to this species.

Infection by the schistosome occurs by the deposition of embolic eggs in the portal venous system for the portal entry. It is here that maturation of the adult worm take place. The urinary bladder is the route to the exterior for *S. haematobium*, the rectum serving *S. Mansoni*. The passage of *S. haematobium* eggs in the urine of infected patients depends on the worm load.³ The mode of spread to the testes is uncertain, but presumably occurs from the infected bladder in a retrograde manner with eggs passed along the vas deferens to the testes. Joshi⁸ thought that maturation might occur in the spermatic venous plexus and that the deposited eggs were carried distally into the smaller vessels of the testis.

Macroscopically the affected testis may suffer fibrous atrophy; in other cases enlargement may occur simulating a testicular tumour. Histopathologically the eggs form the foundation stone around which the bilharzial lesion is organised, and typically in granulomatous lesions, epithelial cells, fibroblasts and inflammatory round cells including plasma cells and eosinophils are arranged in concentric circles round one or several eggs. In the testicle in the early stages focal granulomata may be found, Many tubercles containing calcified spherules may be present. The aetiology of these bodies is at present uncertain.¹⁰ In advanced cases when necrosis, caseation and calcification have occurred the testicular substance is replaced by a white mass of calcified tissue, the normal architecture of the testicle being unrecognisable. The mechanism whereby eggs stimulate the bilharzial lesion is uncertain. Where the adult worms are absent, it is possible that acting as foreign bodies only, secreting no chemical or immune substances granulomata are formed around the eggs.

The management of the patient with a history of testicular enlargement of gradual onset is made more urgent by the need to exclude malignancy. A haematological profile together with biochemical analyses and chest X-rays are essential for diagnosis. Cystoscopy and excretion urography in addition to microscopy of a centrifuged urine specimens will in many cases establish the correct diagnosis, Campbell-Begg¹¹ doubted the value of urine microscopy in assisting diagnosis, arguing that in many cases the urine microscopy was free of eggs, red cells and albumin. Ramsay¹² in Northern Nigeria however found a close correlation between red cells,

leucocytes and albumin in the urine and active *S. haematobium* infection in endemic areas. Diagnosis may also be made by serological tests.¹³ Early exploration through an inguino-scrotal incision is of the utmost urgency in order to exclude a malignant testicular tumour, if a firm diagnosis has not been made by the other methods, Niridazole (ambilhar) is effective in the medical treatment of this disease.^{14, 15}

REFERENCES

1. Dew H R: Observations on the pathology of schistosomiasis (*S. haematobium* and *S. Mansoni*) in the human subject. *J Path and Bact*, 1923; 26: 27-29.
2. Houston W: Bilharziasis of the Testes, *Br J Urol*, 1964; 26: 27-29.
3. Cheever A W, Andrade Z A: Pathological lesions associated with schistosoma *Mansoni* infections in man, *Trans R Soc Trop Med Hyg*, 1967; 61: 626-639.
4. Paget M, Camain R: Bilharziasis, *Internat Acad Path*, Special Monograph, 1967; Pp 133. Berlin, New York Springer.
5. Cowper S C: Schistosomiasis in Nigeria, *Ann Trop Med Parasitol*, 1963; 57: 307-322.
6. Lucas A O, Akpan C A, Cockshott W P, Bohrer S P: Reversibility in children after specific therapy, *Ann NY Acad Sci*, 1969; 160: 629-644.
7. Edington G M: Bilharziasis, *Internat Acad Path*, Special Monograph, 1967; Pp 128. Berlin, New York Springer.
8. Joshi R A: Bilateral total infarction of the Testis due to Schistosomiasis of the Spermatic Cord, *Amer J trop Med Hyg*, 1962; 11: 357-359.
9. Steinberger R M, Lindsay K G, Alassandri R: et all. Infarction of testicle and schistosoma *Mansoni*, *Urology*, 5: 567-569.
10. Priebe C J, Garret R: Testicular Calcification in a 4-year old boy, *Paediatrics*, 1970; 46: 785-788.
11. Campbell-Begg R: Bilharzia Disease: Some Prevalent Misconceptions, *S Afri Med J*, 1944; 18: 239-241.
12. Ramsay G St C: A study of schistosomiasis and certain other helminthic infection in Northern Nigeria, *W Afr Med J*, 1934/35; 8: 2-10 (1934), 2-7 (1935).

13. Fi-Sumyer T X, Giles H M, Wilson A M M: S. haematobium infection in Nigeria. I. Bacteriological and Immunological findings in the presence of schistosomal infection, *Ann Trop Med Parasit*, 1965; 59: 304–311.
14. Davis A: Field Trials of Ambilhar in the Treatment of Urinary Bilharziasis in school children, *Bull Med W. Hlth Org*, 1966; 35: 827–835.
15. Giles H M: Niridazole, *The Practitioner*, 1969; 200: 451–453.



This work is licensed under a
Creative Commons
Attribution – NonCommercial - NoDerivs 3.0 License.

To view a copy of the license please see:
<http://creativecommons.org/licenses/by-nc-nd/3.0/>

This is a download from the BLDS Digital Library on OpenDocs
<http://opendocs.ids.ac.uk/opendocs/>