



# THE CENTRAL AFRICAN JOURNAL OF MEDICINE

Vol. 61, Nos. 1/4

CONTENTS

January/April 2015

## ORIGINAL ARTICLES

Prevalence and the correlates of postnatal depression in an urban high density suburb of Harare.....

J January, H Chivanhu, J Chiwara, T Denga, K Dera, T Dube, V Chikwasha, TM Chikwanha..... 1

Etiology and risk factors of meningitis in patients admitted at a Central Hospital in Harare.....

A Matubu, S Rusakaniko, V Robertson, L Gwanzura.....5

Effects of different frequencies of loading on healing in partial rupture of the Achilles tendon in a rat model.....

NS Mkumbuzi, HM Chinyanga, W Wood, SKT Mudambo, M Gova..... 11

An echocardiography audit to determine and characterise rheumatic heart disease lesions seen in 2012.....

NT Munyandu..... 17

## CASE REPORT

Bilharzioma of the fallopian tube: a case report.....

R Makunike-Mutasa, K Phiri.....21

## NOTES AND NEWS

Instructions to Authors.....

*Central African Journal of Medicine*.....23

# CASE REPORT

## Bilharzioma of the fallopian tube - a case report

R MAKUNIKE-MUTASA, K PHIRI

### Introduction

*Schistosomiasis*, also known as bilharzia is an infection caused by trematode flatworms of any species of the genus *Schistosoma*. At least 261 million people in 74 countries are infected, and of these, 90% are in Sub-Saharan Africa.<sup>1</sup> In Zimbabwe, the prevalence is 38,2% for *S. haematobium* and 8,3% for *S. mansoni*.<sup>2</sup> A “bilharzioma” is a localised mass of fibrous and inflammatory tissue, which contains numerous eggs frequently involving the serosa and mesentery.<sup>3,4</sup> *Schistosomiasis* caused by *Schistosoma haematobium* generally is asymptomatic, and if symptomatic, presents with terminal haematuria and rarely with other symptoms.<sup>5</sup> Even in endemic areas, very rarely, will *Schistosomiasis* result in formation of a “bilharzioma”.<sup>3</sup> The most commonly reported site is the intravesical part of the ureter resulting in stricture formation, but rarely bilharziomas are found in other sites including the female genital tract. Here we report a case of a “Bilharzioma” masquerading as a malignant tumour with seedlings in the fallopian tube.

*Cent Afr J Med* 2015;61(1/4):21-23

### Case Report

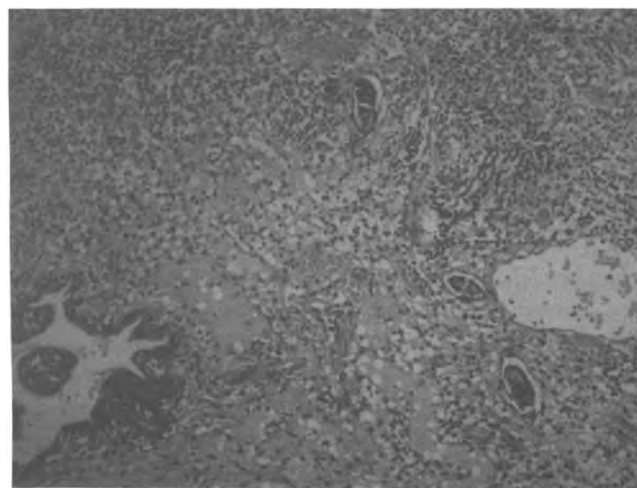
We present a 37 year old, Caucasian woman who presented to a gynaecologist with a history of amenorrhea and subsequent per vaginal bleeding. In her gynaecological history, she was Gravida 3, Para 2, and her youngest child was 12 years old. Her periods had always been regular and she had a copper T contraceptive device in situ. She missed her period and subsequently had a PV bleed. She was found to have an incomplete abortion, for which a D&C and removal of the IUCD, as well as ligation fallopian tubes was arranged. At laparoscopy, she was found to have a 30mm “tumour at” the fimbrial end of her left fallopian tube. A mini-laparotomy was performed to remove the “tumour”, and seedlings on the contralateral fallopian tube, adjacent ovary as well as on the uterine surface. Peritoneal nodules were also seen but no peritoneal fluid was evident. The “tumour” was resected, and the following day post-operatively, the patient was counselled for a TAH and BSO and consent was obtained.

### Pathological findings

The resected “tumour” was sent for histological analysis. A 25mm by 30mm firm mass with a “cauliflower appearance” was received. On cut

surface, it was white with yellow flecks and a rather gritty consistency. Three representative sections of the mass were taken. Histology revealed florid peri-serosal granulation tissue with chronic inflammation and numerous schistosoma ova (Figure I).

*Figure I: Fallopian tube mucosa with schistosoma ova set in a chronic inflammatory background x 10 magnification.*



Many of the ova were calcified accounting for the gritty cut surface, and the ova did not take up the Modified Ziehl Neelson stain consistent with *Schistosoma*

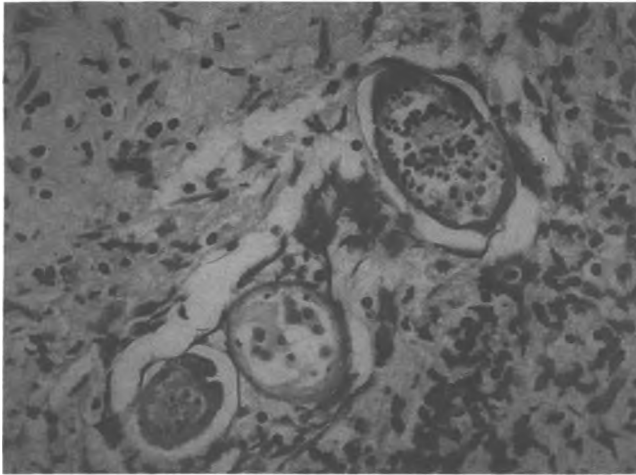
*Corresponding to:*

*Dr R Makunike-Mutasa  
Department of Histopathology  
University of Zimbabwe, College of Health Sciences  
P O Box A178, Avondale, Harare  
Zimbabwe*

*Department of Histopathology  
University of Zimbabwe, College of Health Sciences  
P O Box A178, Avondale, Harare  
Zimbabwe*

Haematobium (Figure II). The fimbriae were uninvolved, and there was no evidence of malignancy. A diagnosis of “Bilharzioma” was made.

Figure II: *Schistosoma haematobium*, with terminal spines x 40 magnification.



## Discussion

*Schistosomiasis* is an infection caused by a trematode and is endemic in Sub Saharan Africa. There are two major forms of *Schistosomiasis*; intestinal and urogenital, caused by five main species of blood flukes, *S. Haematobium*, *S. Mansoni*, *S. Japonicum*, *S. Mekongi*, *S. Guineensis* and related intercalatum, with *Mansoni*, *Haematobium* and *Japonicum* being the commonest. The earliest case of human *Schistosomiasis* was described over 5000 years ago around 1200 BC, in an Egyptian adolescent mummy.<sup>6</sup> The life cycle of this trematode involves an intermediate host (snail) that carries the miracidium after the egg has hatched following contact with water, releasing the miracidium to enter the snail. The miracidium matures into a sporocyst and is released into water as cercaria, which penetrate the human skin and becomes a schistosom. The schistosom migrates to the portal blood and then matures into adult worms. The paired adult worms then migrate to the peri-vesical blood plexus, and release numerous eggs that penetrate tissues. Half of the hatched eggs are excreted in urine, and the other half lodge in the genitourinary system with a portion being embolised to distant sites. The eggs elicit a granulomatous reaction with abundant eosinophils.

When the infection results in formation of a tumour mass, this is referred to as a “Bilharzioma”. “Bilharziomas” are thought to be caused by a reaction to eggs produced by one or more pairs of worms in a single site, although altered host reactivity may also be a factor. The term “Bilharzial polypi” was first coined in 1856 in Egypt after a German naturalist, Theodor Maximillian Bilharz. Later, in 1950, Michael Gelfand working in Zimbabwe (then, Rhodesia), suggested the

term “Bilharzioma” a term, that continues to be used worldwide.<sup>3,7</sup>

“Bilharziomas” were classically described as tumour masses occurring in the transvesical ureter. Several reports have been made of tumour masses occurring in other sites including, Breast,<sup>8</sup> spinal cord,<sup>9</sup> lung,<sup>10</sup> intestine,<sup>11</sup> and the genital and perineal areas.<sup>12,13</sup> Bilharziomas are usually asymptomatic until they cause obstruction and are often picked up incidentally as in this case. They are not generally associated with constitutional symptoms, such as weight loss, pyrexia, etc., although these have been reported. Sometimes, patients have other abnormalities including a raised WBC count with eosinophilia, but Michael Gelfand reported eosinophilia in only 50% of cases of bilharzioma in Zimbabwe.<sup>3</sup>

## Conclusion

We report an unusual case of *Schistosomiasis* presenting as a “tumour”, which is an important differential diagnosis for tumour masses seen in the adnexae of women living in endemic areas. In the era of widespread use of imaging ( Plain X Rays, Ultra Sound Scans, CT scans, and MRI Scans) a mass which on radiology, exhibits calcification may well be confused for a malignant tumour. Calcification is used as a marker for malignancy in breast lesions as well as in papillary carcinomas of the ovary where psammoma bodies are responsible for the calcification seen on imaging. One of the authors (RM) previously reported a case of *Schistosomiasis* in the breast of a Zimbabwean female that had been picked up on mammographic screening for cancer. In this case, malignancy was erroneously suspected, not only because of the mass, but also the presence of a “cauliflower appearance”, calcification, as well as the presence of seedlings. These appearances would have been typical of a papillary serous carcinoma of ovary with psammoma bodies.

This case highlights two important points:

- i) The importance of histological evaluation of any radiologically diagnosed condition, no matter how clinically suspicious it is, and;
- ii) That *schistosomiasis*, an age old disease, still exists and may not only cause serious morbidity, but may mimic a malignant lesion leading to over-treatment, which may compromise fertility, and result in unnecessary morbidity associated with major operative procedures.

## References

1. Chitsulo L, Engels D, Montresor A, Savioli L. The global status of *Schistosomiasis* and its control. *Acta Tropica* 2000;77(1): 41-51.

2. Tylor P, Makura O. Prevalence and distribution of *Schistosomiasis* in Zimbabwe. *Ann Trop Med Parasitol* 1985;79(3):287-99.
  3. Gelfand M, Juta and Co. Ltd. *Schistosomiasis* in South Central Africa: a clinico-pathological study. Cape Town and Johannesburg. *Schistosomiasis of the female genitalia*, 1950;6:203-8.
  4. Al-Ghorab MM. Radiological manifestation of genitourinary bilharziasis. *Clin Radiol* 1968;19(1):100-11.
  5. Gelfand M. The diagnosis and prognosis of *schistosomiasis*. *Am J Trop Med* 1949; 51(6):945-58.
  6. Deelder AM, Miller RL, Dejonge N, Krijger FW. Detection of schistosoma antigen in mummies. *Lancet* 1990;335:724-5.
  7. El-Badawi AA. Bilharzial polypi of urinary bladder. *Br J Urol* 1966;38(1):24-35.
  8. Makunike R, Muronda C. Breast *schistosomiasis*: a case report. *Histopathol* 2002;40(2):175-6.
  9. Antonio CM, Maia Jr MD, Luciano RF, Silva MD, Matheus D, Guimaraes MD, et al. Spinal cord compression secondary to epidural bilharzioma: case report. *Neuroimaging* 2007; 17(4): 367-370.
  10. Tompson HT, Pettigrew RR, Johnson EA. Solitary pulmonary bilharzioma. *Thorax* 1979;34:401-2.
  11. Elmasaline FN, Raheen MA, Badaw G, Suberi SR, Matboul J. Rectosigmoid bilharzioma causing intestinal obstruction. *Paediatr Surg* 1979;32(4):631-3.
  12. Daa Self-Eldin. Bilharziasis of the fallopian tubes and ovaries. *Int J Obstetr Gynaecol* 2005;65(3):457-9.
  13. Mouktar M. Functional disorders due to bilharzial infection of the female genital tract. *BJOG* 2005;73(2):307-10.
-



This work is licensed under a  
Creative Commons  
Attribution – NonCommercial - NoDerivs 3.0 License.

To view a copy of the license please see:  
<http://creativecommons.org/licenses/by-nc-nd/3.0/>

This is a download from the BLDS Digital Library on OpenDocs  
<http://opendocs.ids.ac.uk/opendocs/>